

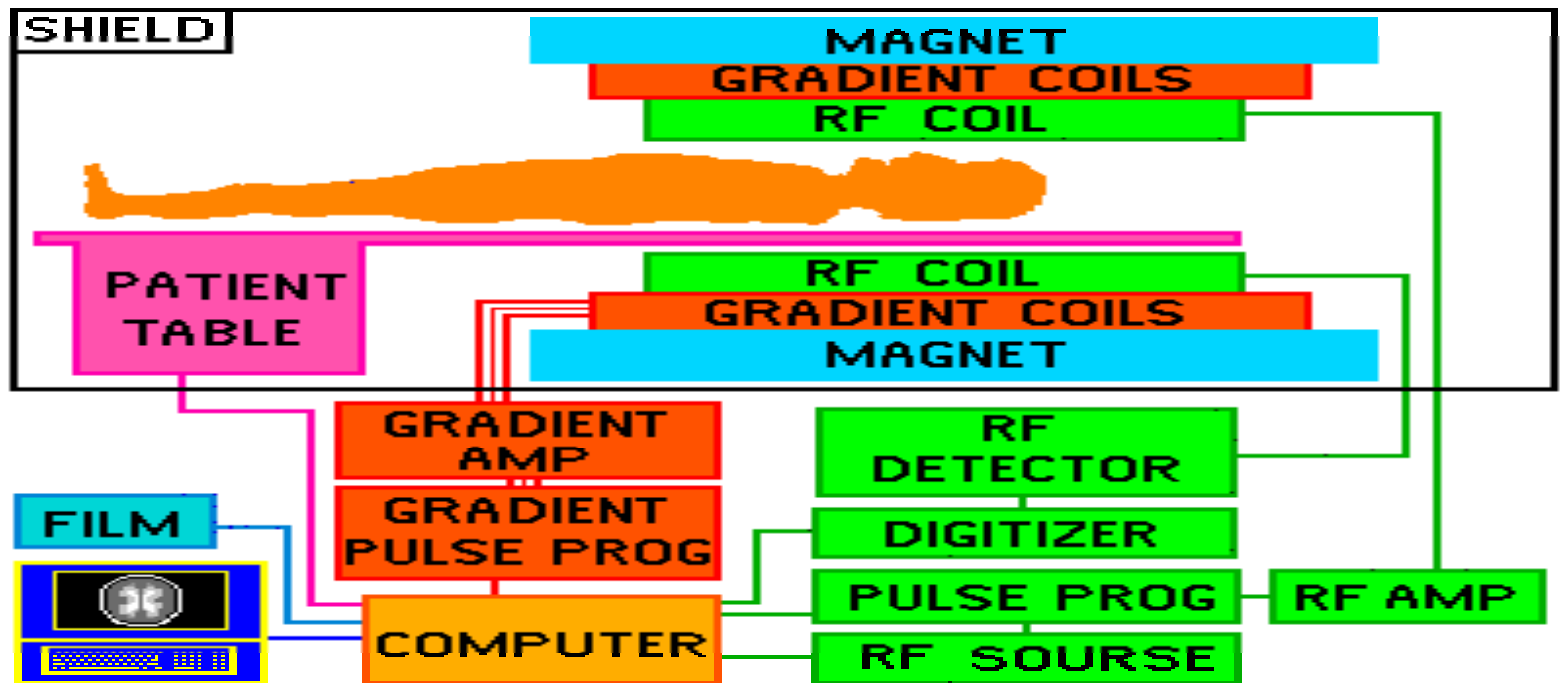
NEWER MR TECHNIQUES & THEIR ROLE IN NEUROSURGERY

DR SAURABH SHARMA
Moderators

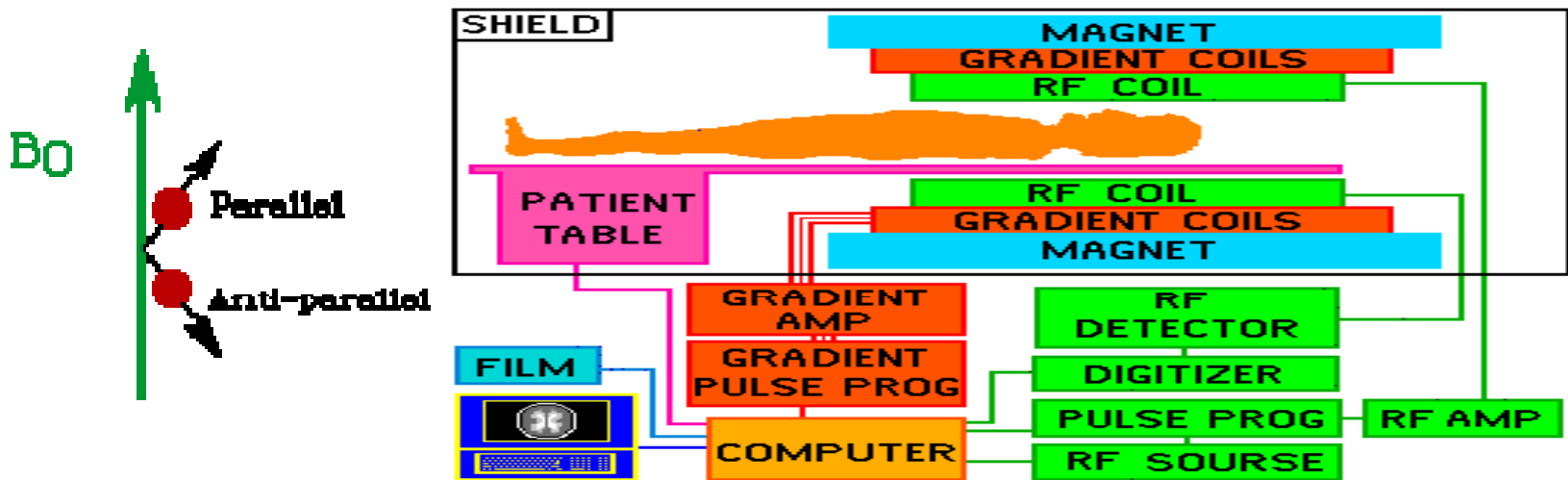
DR SHASHANK S. KALE
DR MANISH S SHARMA

BASICS OF MRI

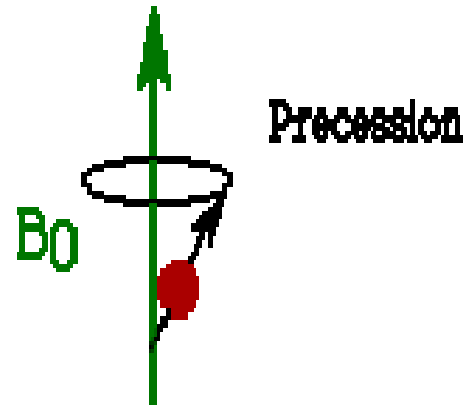
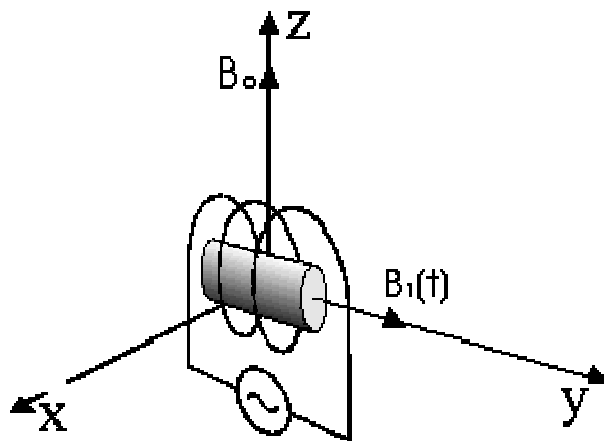
- Based on complex interaction between
 - Protons in human body
 - Magnetic field
 - Radiofrequency energy



- The body is largely composed of water which contain 2 protons in each molecule.
- When a person goes inside the powerful magnetic field of the scanner, the magnetic moments of these protons align with the direction of the field .



- A radio frequency electromagnetic field is then briefly turned on, causing the protons to alter their alignment relative to the field.
- When this field is turned off the protons return to the original magnetization alignment.
- *Precession* : Wobbling sort of motion undergone by spinning object ,frequency of precession is called the Larmor frequency

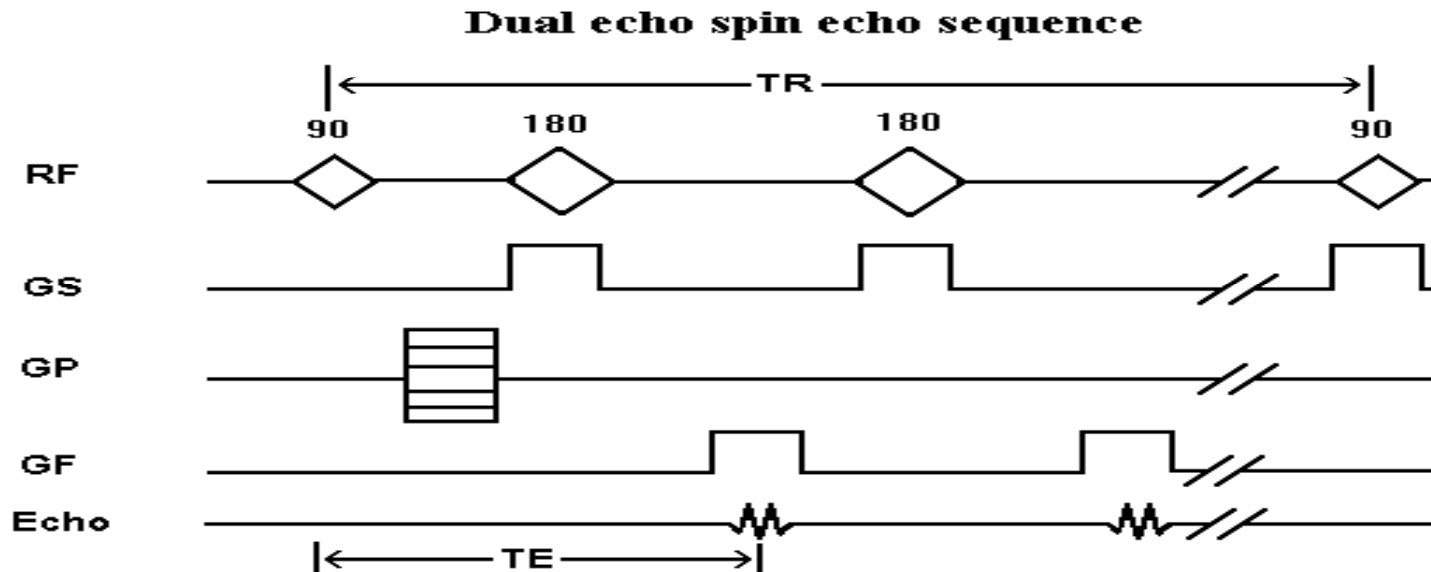


- These alignment changes create a signal which can be detected by the scanner.
- The frequency at which the protons resonate depends on the strength of the magnetic field
- The position of protons in the body can be determined by applying additional magnetic fields during the scan which allows an image of the body to be built up.
- *These are created by turning gradient coils on and off which creates the knocking sounds heard during an MR scan*

BASIC TERMINOLOGY

- **SPIN ECHO**

- TR (Repetition Time): Interval between Rf pulses.
- TE (Echo time): Time between Rf pulse & signal reception.



- **Fast spin echo:** decreased scan time by increasing efficiency of data collection. Collects multiple views in each TR time (echo train length).
- With increased efficiency image contrast may decrease.
- To image uncooperative patient single shot FSE may be used.
 - T2*
 - **Inversion recovery** - allows to eliminate the signal of tissues according to their T1 time by choosing an appropriate TI.
- FLAIR (Fluid attenuated inversion recovery)
 - STIR (Short tau inversion recovery)

- **ECHOPLANAR IMAGING:**

- Single excitation used to collect all multiple images(40ms)
- Used in applications highly sensitive to even minor proton movement.

USED IN:

- ❖ Diffusion MR
- ❖ Perfusion MR
- ❖ Functional MR

- **GRADIENT ECHO**

- An excitation pulse with a flip angle lower than 90°
- No 180° rephasing pulse
 - TR is very short and scan time very less (sec).
 - » Visualize hemosiderin and ferritin
 - » MRA
 - » CISS (Constructive interference in steady state).

	TE	TR	
T1	00	000	T123
T2	000	0000	T234

T1 WI: TR & TE short

T2 WI: TR & TE long

T1 WI: **Dark - Water, CSF, edema, Calcium(can be paradoxically bright because of crystalline structure of calcium)**

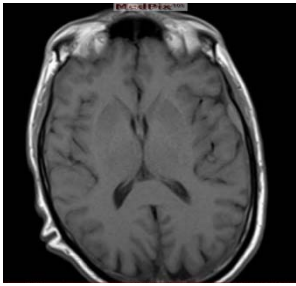
Bright - Lipid ,Gadolinium, subacute blood, protein, Mn, melanin

T2 WI: **Dark - Calcium, bone**

Bright - CSF, water, edema

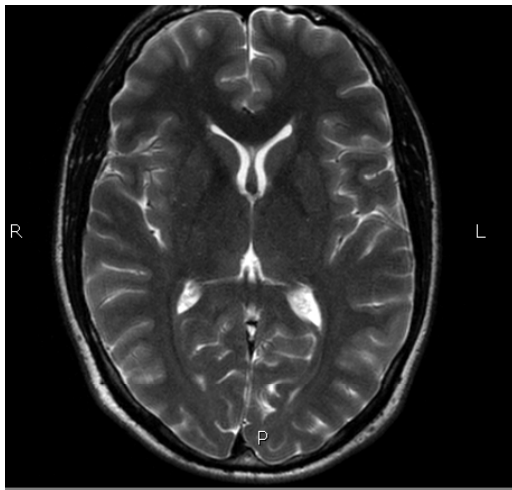
AIM

- DECREASING TIME WITHOUT COMPROMISING QUALITY
- FUNCTIONAL IMAGING



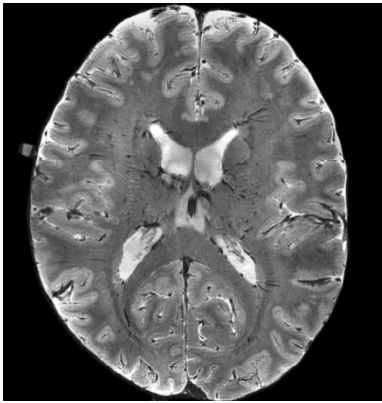
T1-weighted MRI

- Use a (GRE) sequence, with short TE and short TR .
- Basic types of MR contrast and is a commonly run clinical scan.
- The $T1$ weighting can be increased (improving contrast) with the use of an inversion pulse as in an ***MP-RAGE sequence***.
- Due to the short repetition time (TR) this scan can be run very fast allowing the collection of high resolution 3D datasets.
- Gadolinium contrast agent is also commonly used
- Provide good gray matter/white matter contrast.(ANATOMY)



T2-weighted MRI

- Use a [spin echo](#) (SE) sequence, with long $T E$ and $T R$.
- They have long been the clinical workhorse as the spin echo sequence is less susceptible to inhomogeneities in the magnetic field
- They are particularly well suited to edema as they are sensitive to water content (edema is characterized by increased water content):**PATHOLOGY**



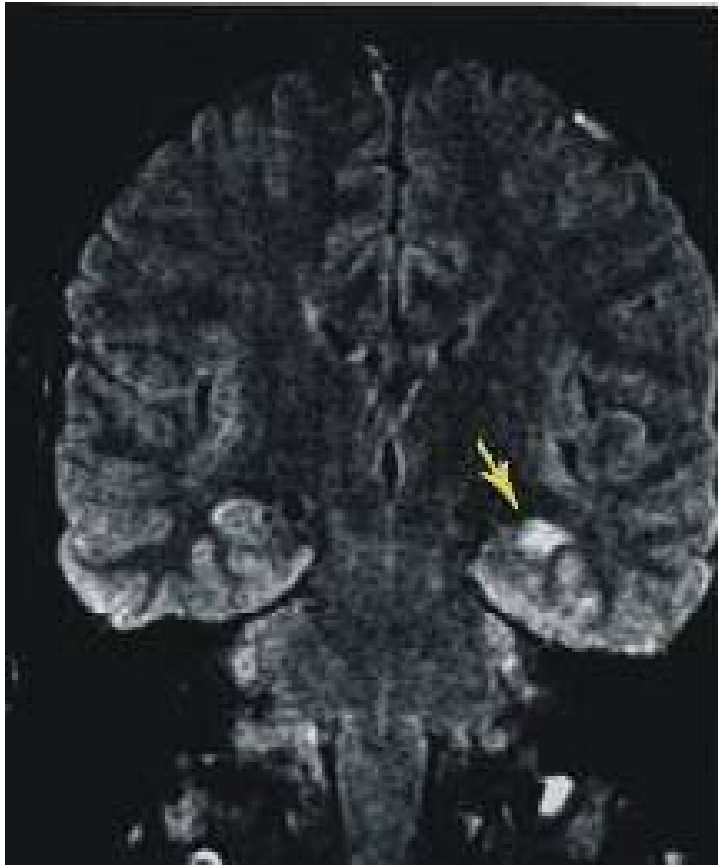T^*2 -weighted MRI

- T^*2 (pronounced "T 2 star") weighted scans use a (GRE) sequence, with long TE and long TR .
- The gradient echo sequence used does not have the extra refocusing pulse used in spin echo so it is subject to additional losses above the normal $T2$ decay (referred to as $T2'$), these taken together are called T^*2 .
- This also makes it more prone to susceptibility losses at air/tissue boundaries, but can increase contrast for certain types of tissue, such as venous blood

FLUID ATTENUATED INVERSION RECOVERY (FLAIR)

- sequence used to null signal from fluids. E.g. CSF so as to bring out lesions at fluid-parenchyma interface
- choosing the inversion time TI (the time between the inversion and excitation pulses), the signal from any particular tissue can be suppressed
- **CLEAR FLUID in a CLOSED SPACE will be suppressed**
- **FAST FLAIR:**
 - Fast spin echo plus flair

USES

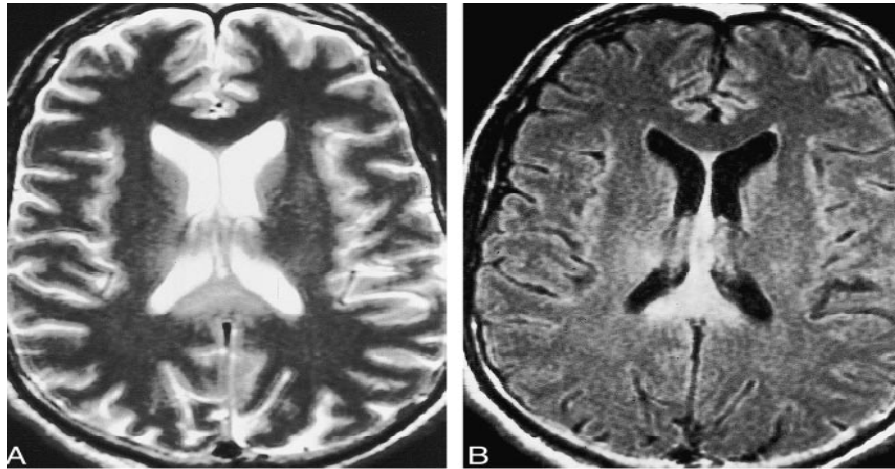


1. *For periventricular & subcortical abnormalities:* (Cortical & juxtacortical multiple sclerosis lesions, degenerative diseases).
2. *In seizure disorders (e.g MTS):*
 - Sensitive for detecting signal abnormalities demonstrating size asymmetry & abnormal signal within the atrophied hippocampus.

3. *FLAIR MR may be helpful in differentiating epidermoid from arachnoid cyst*

Signals of epidermoid being similar to that of brain parenchyma ,arachnoids cyst signal suppressed.

4. *Diffuse axonal injury: White matter lesion volume can be quantitatively assessed. Patients with greater DAI volume have poorer functional outcomes.*

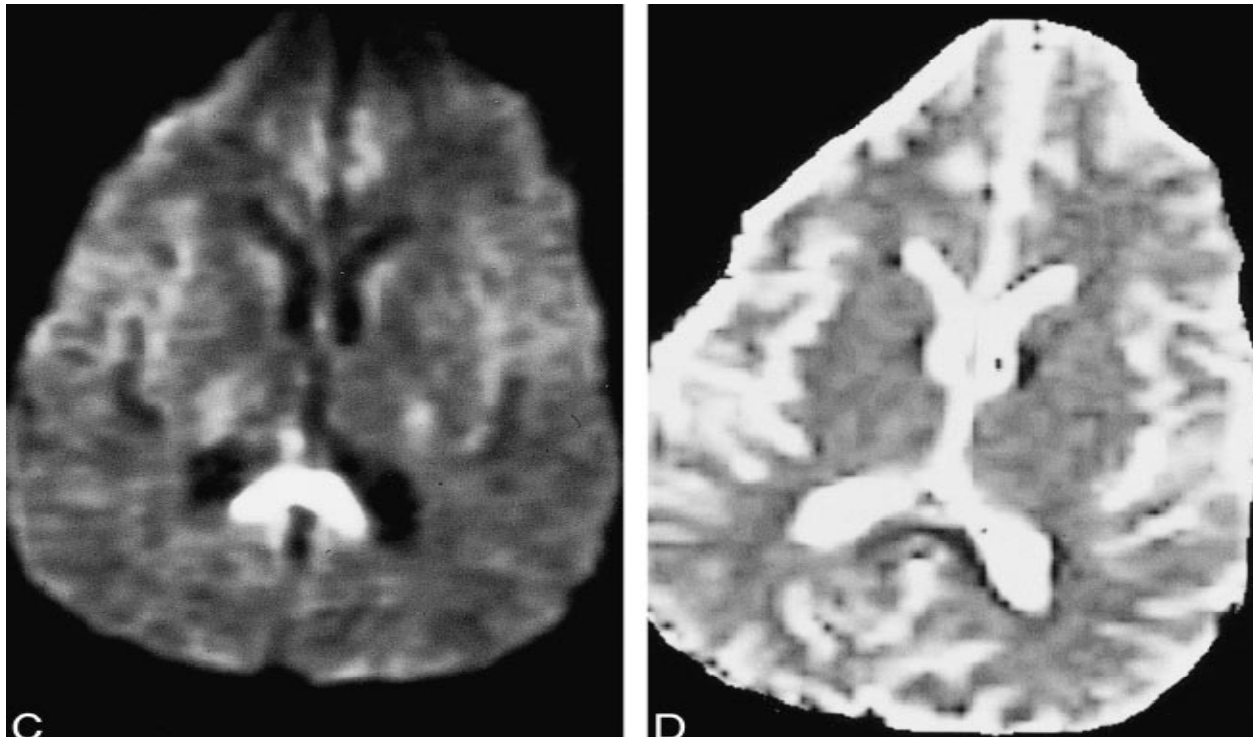


A and B, Axial fast spin-echo T2-weighted (A) and FLAIR (B) images both show evidence of diffuse axonal injury, as evidenced by hyperintense signal in the splenium.

5 *Stroke* : Hyperintensity on FLAIR as early as 4-6 hrs after ictus & T1, T2 - normal.

Slow-flowing arteries are depicted by FLAIR as hyperintensities against darker brain tissue, leading to the "hyperintense vessels sign" (HVS).

HVS is a reversible sign, with hypoperfusion without infarction.



DRAWBACKS

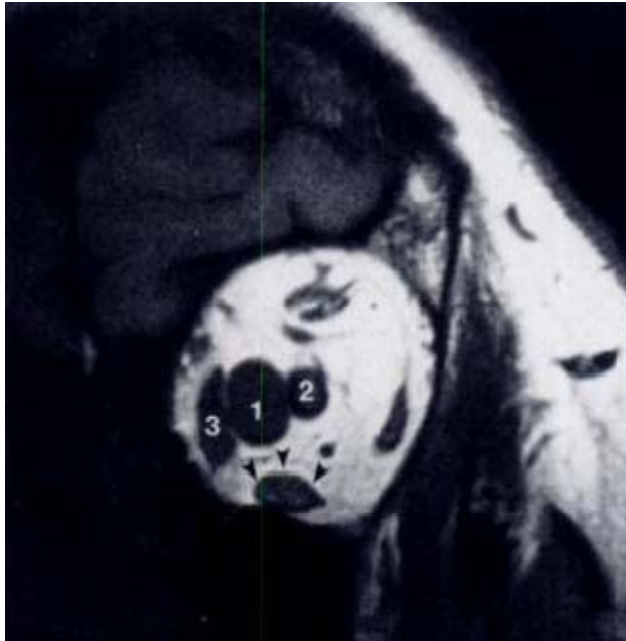- Artifactual increased signal in and around CSF spaces limits its role in posterior fossa.
- Incomplete nulling of CSF signals due to CSF inflow effects produces imaging artifacts.
 - Areas of prominent CSF pulsatility, such as inferiorly located sections and those containing foramina of the CSF ventricular system.
 - May not detect lesions located in the brain stem.
- Poor lesion contrast may be present
 - In the basal ganglia & posterior fossa (particularly MS plaques), & the inability to clearly depict cystic lesions.

FAT SUPPRESSION SEQUENCE

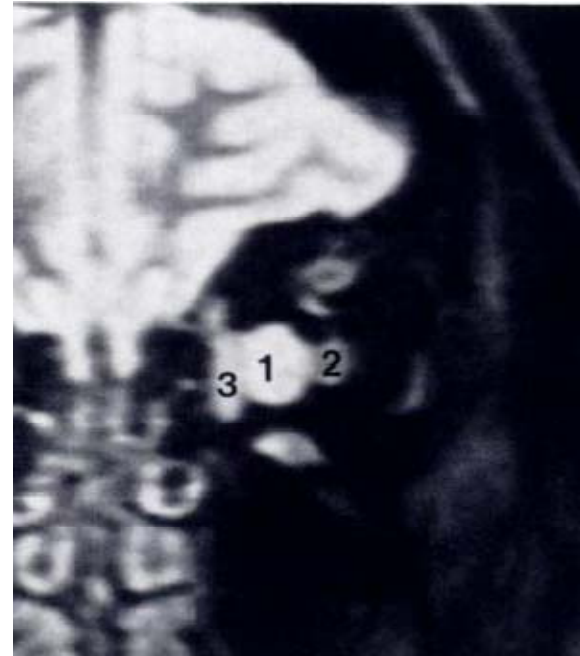- Short tau inversion recovery (**STIR**) -Using adequate inversion time (100-150ms) signal from fat is suppressed while it becomes very sensitive to change in water content.
- Uniform & consistent fat suppression and excellent T2-like contrast when long repetition times are used.

USES

1. Lesions in the optic nerve can be visualized e.g. traumatic, demyelinating.

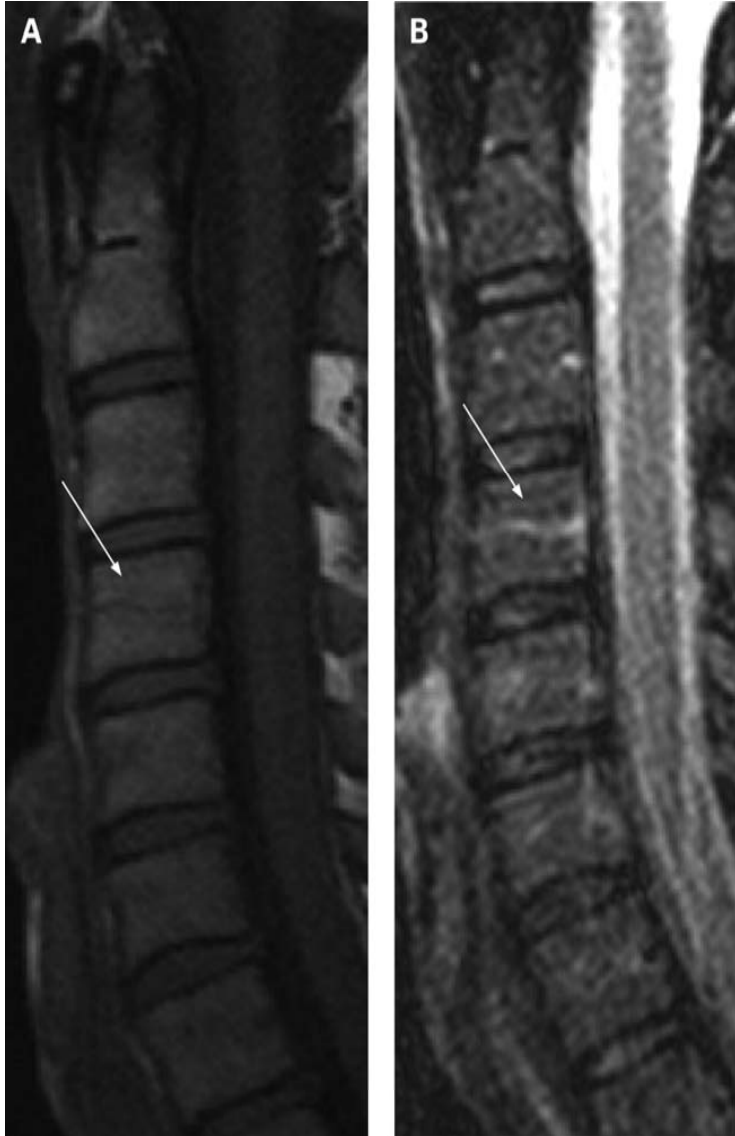


Well-circumscribed **mass (1)** is well delineated between **optic nerve (2)** and **medial rectus muscle (3)** **Mass is isointense relative to muscle on short TRITE (T1W)**



Mass is hyperintense relative to fat, but approximately isointense relative to muscle, on STIR image

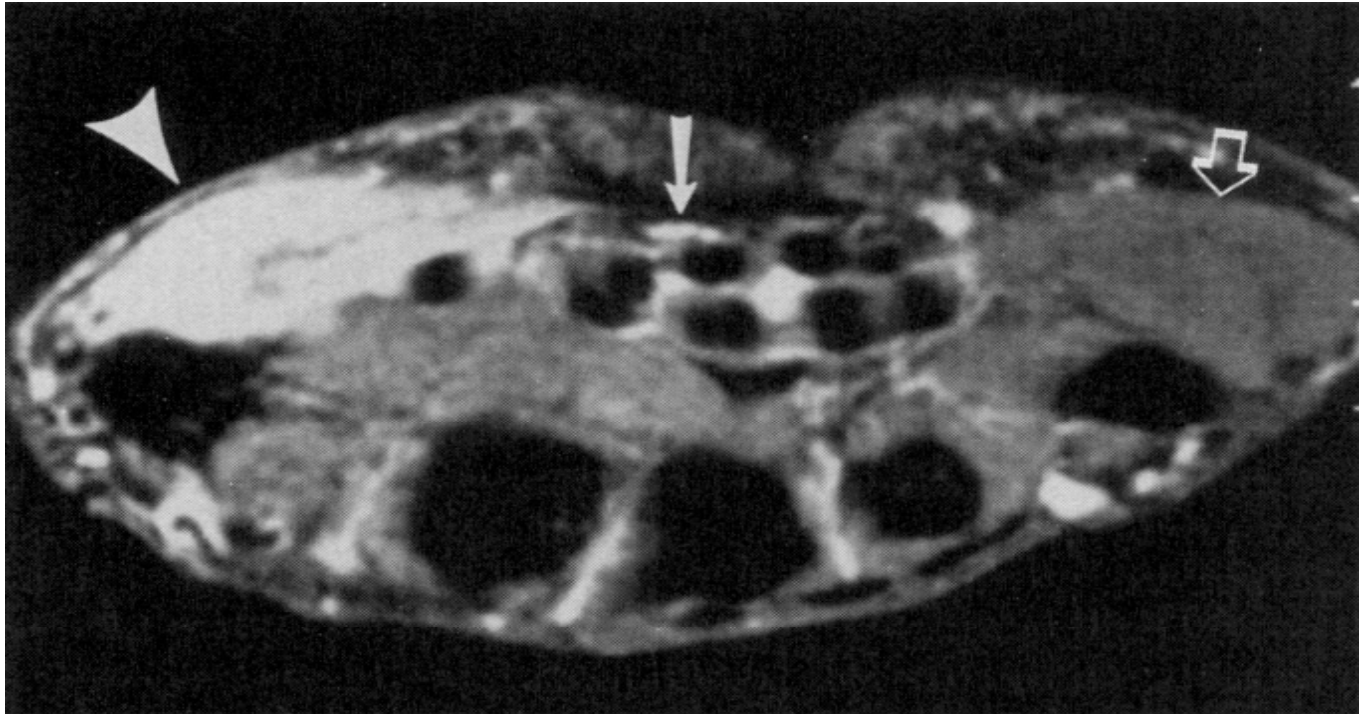
USES



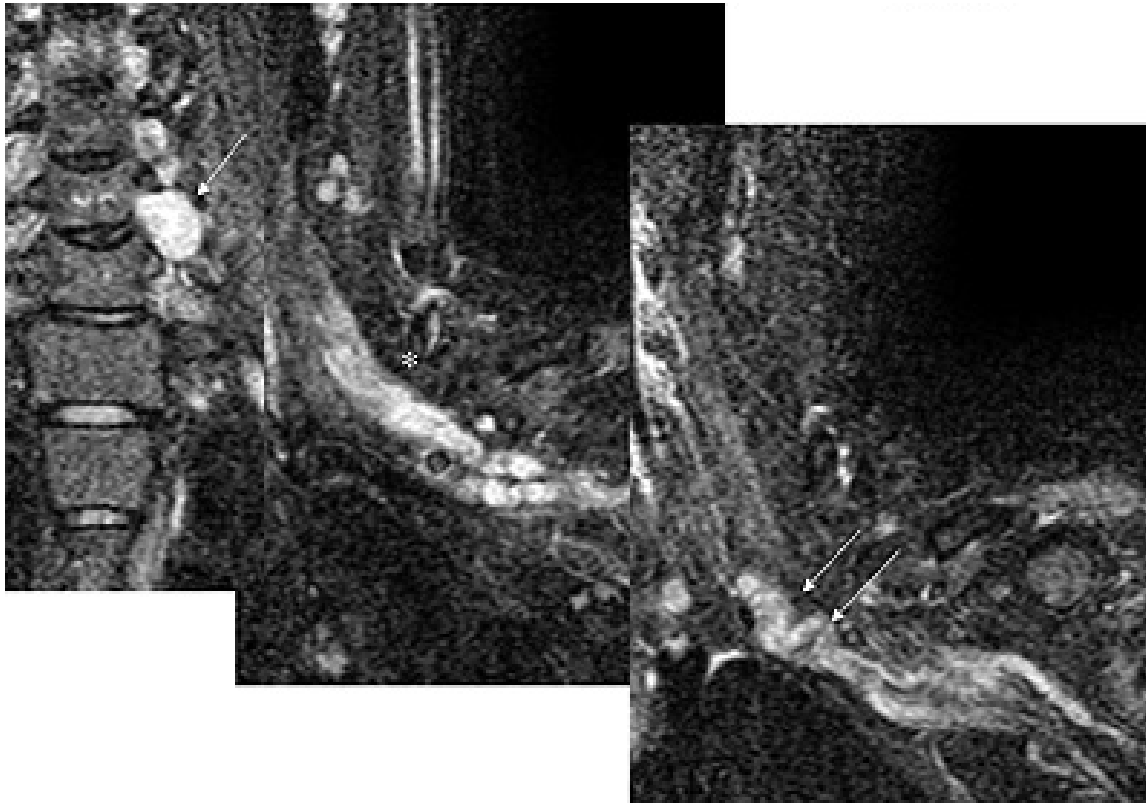
2. Metastasis to vertebral body in fatty marrow
 - These can be missed on T2.
3. Useful for fractures of vertebral body.
4. Useful in carpal tunnel syndrome & brachial plexus injury (in 2 planes – direct coronal & oblique sagittal).
5. Musculoskeletal imaging.

USES

4. Useful in carpal tunnel syndrome . Carpal tunnel syn. – flattened median nerve & signal from denervated muscles



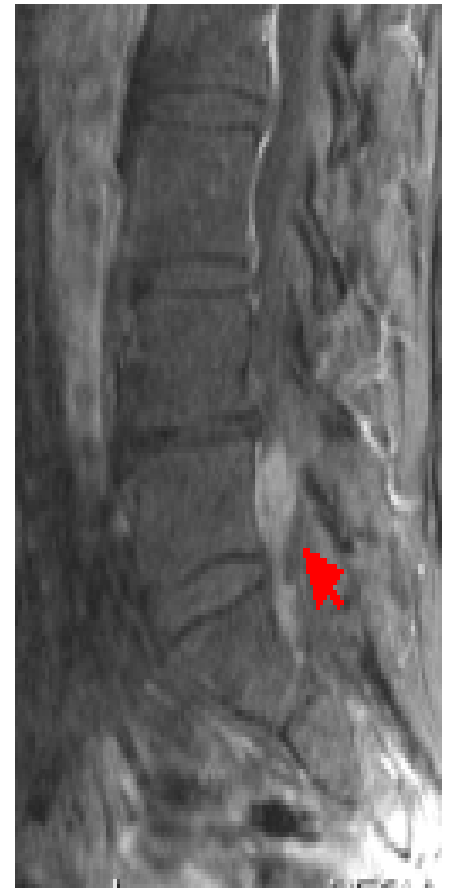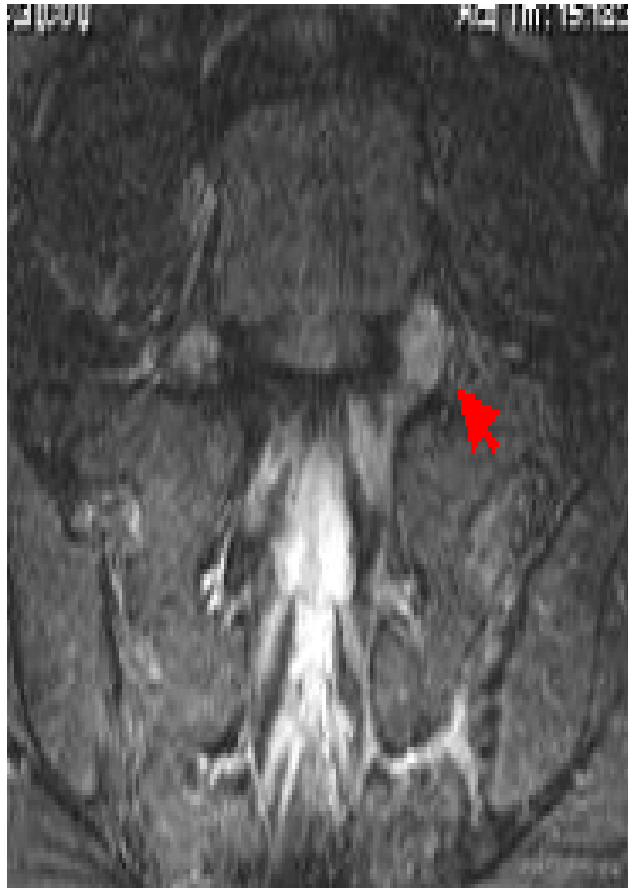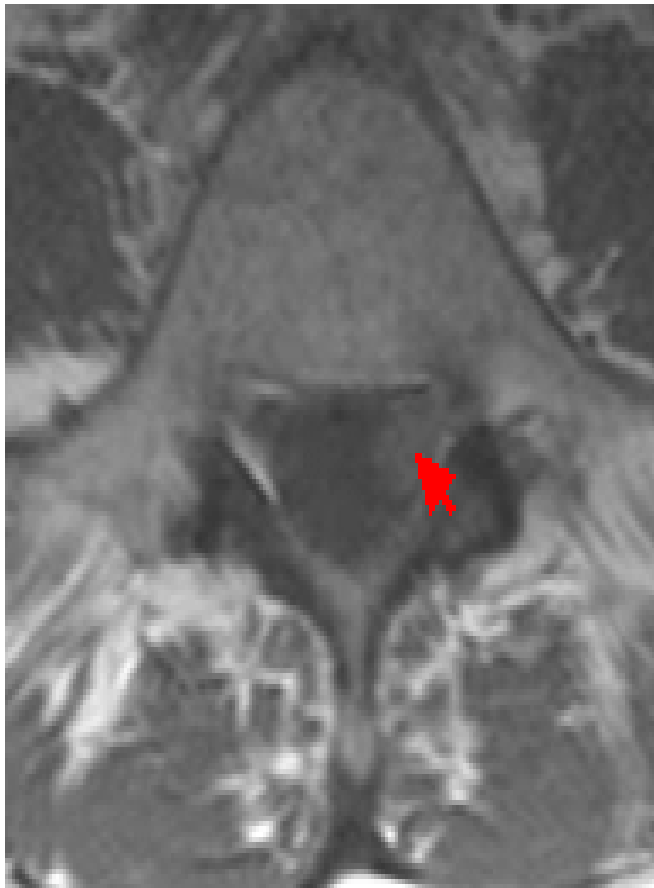
BRACHIAL PLEXUS INJURY



- Coronal STIR sequences through the left brachial plexus in a 19-year-old male after a motorcycle accident

- There is a left C7 pseudomeningocele (*arrow*) with retraction of the distal C7 root & middle trunk (*double arrow*). Enlargement & abnormal signal are also seen in the left C5 & C6.

A dumbbell shaped enhancing IDEM mass (arrow) appearing isointense on T1W and hyperintense on STIR



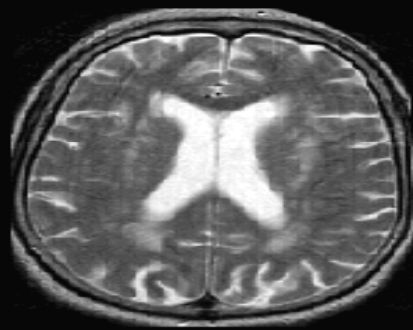
DIFFUSION MRI

- Based on echo planar imaging.
- Diffusion of contrast depends on Brownian motion of free proton.
- **Restriction of motion appears as high signal intensity.**
- Water molecules that are not “restricted” will have greater net diffusion over a given period of time than water molecules surrounded by cell organelles membranes, large proteins etc.
- **High signal is inversely proportional to ADC.**

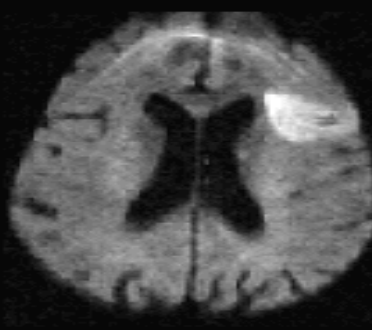
USES

- DWI is highly sensitive in identifying hyperacute(0-6hr) & acute infarction(6-24hr), within minutes of occlusion, while conventional MRI takes 6-10 hours. MRI can help to define :
 - acutely ischemic region (DWI)
 - the tissue at risk for further ischemia (PWI)
 - vascular anatomy (MRA)

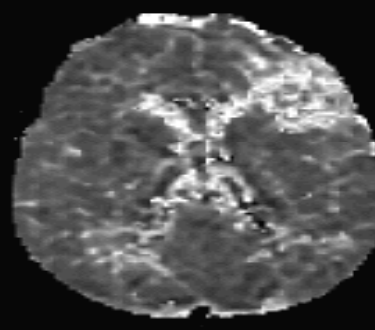
78 y.o. female 3 hours after acute onset of aphasia during cardiac catheterization



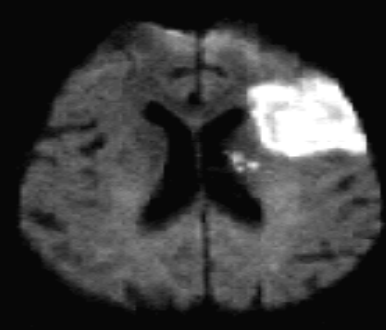
T2 FSE



Initial DWI



Initial MTT

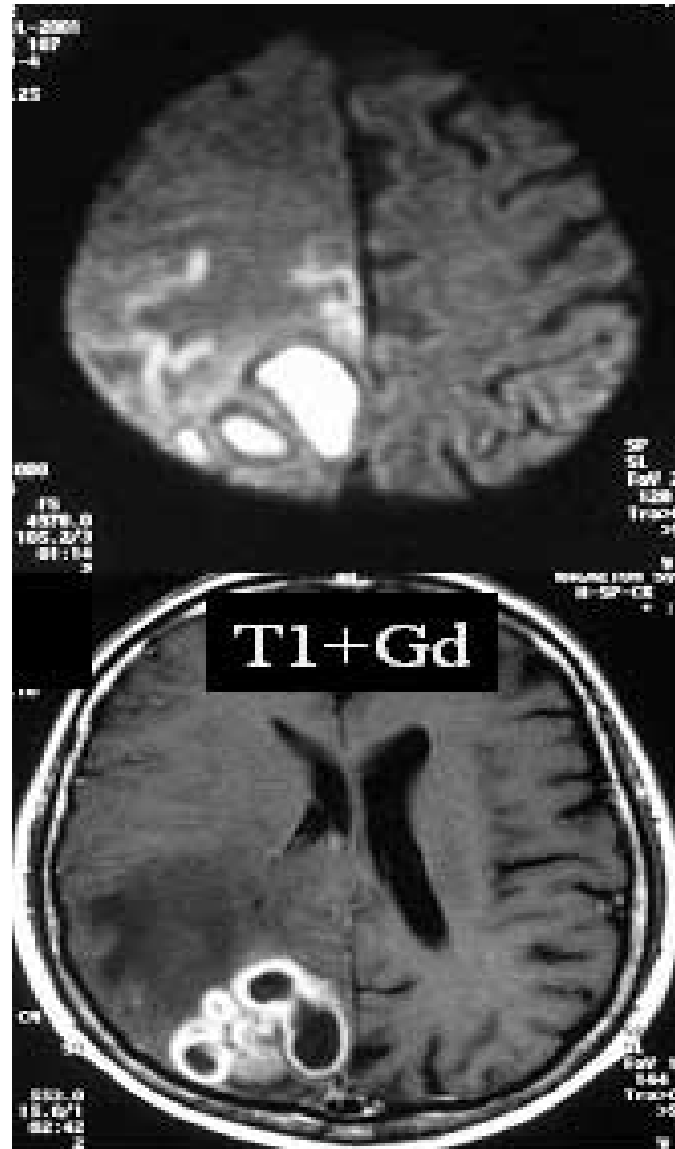


**Follow-up DWI
(5 days later)**

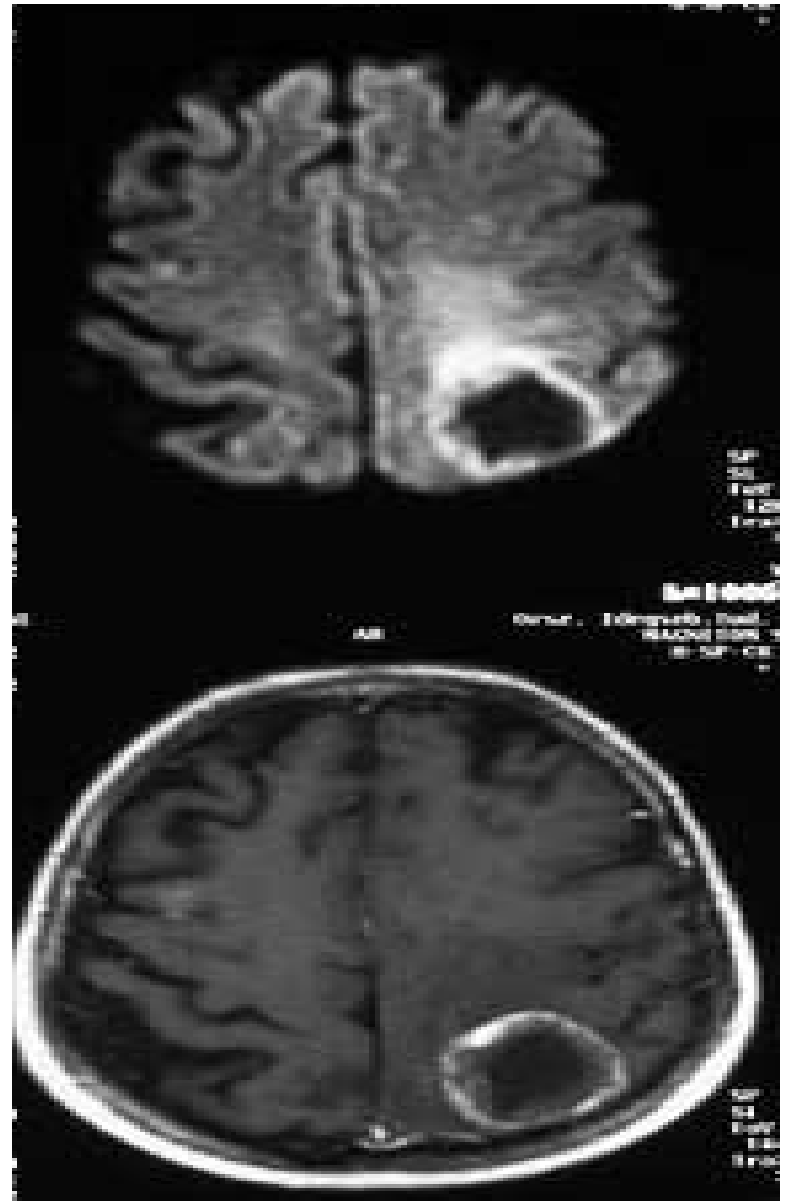- Abscess shows : decreased diffusion & increased signal intensity.

Abscess cavity: numerous WBCs & proteinaceous fluid with high viscosity.

- Restricted diffusion - low ADC values high signal intensity on DWI.



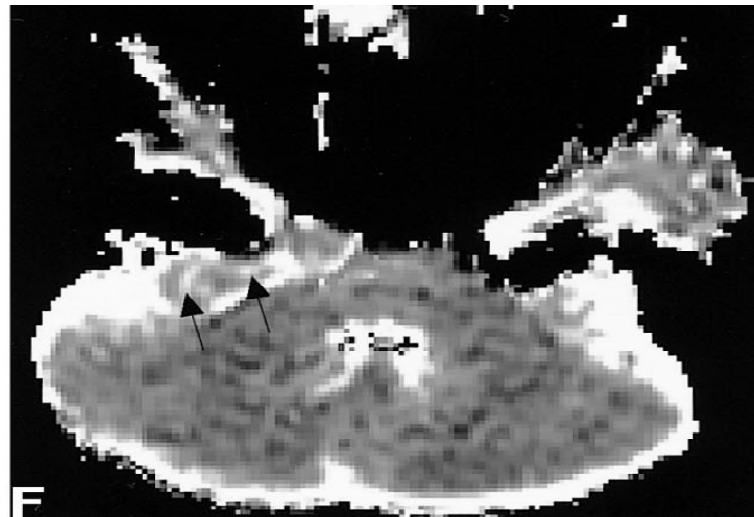
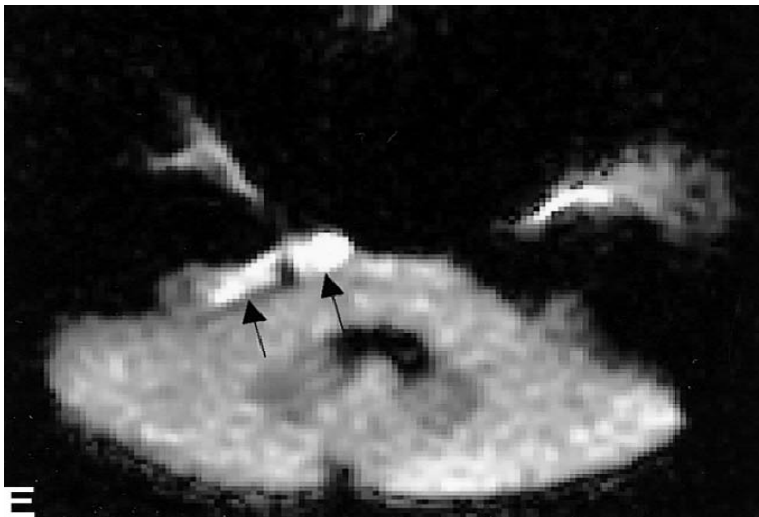
- Necrotic or cystic tumors (**low SI, high apparent diffusion coefficient (ADC)**)
 - In contrast, the cystic or necrotic portions of brain tumors : less cellular and have less viscous fluid consistency.
 - Tumors show low signal intensity on DWI and higher ADC values.



- DWIs allow easier differentiation of the Arachnoid cyst vs. epidermoid

CSF contents of arachnoid cysts results in low signal intensity on DWI

Epidermoid cysts have a high signal on DWI.



E, Echo-planar DW imaging reveals the tumor as a sharply hyperintense lesion (arrows) relative to the brain and CSF.

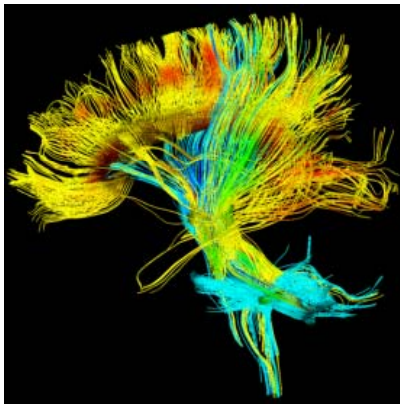
F, ADC map shows that the intensity of the tumor is similar to that of surrounding brain tissue but much different from that of CSF.

MR Imaging Characteristics and Suggestive Features of Lesions Arising from the Cerebellopontine Cistern

Lesion	T1-weighted	T2-weighted	Enhancement	Suggestive Features
Epidermoid cyst	Hypointense	Hyperintense	No	Hyperintense on diffusion weighted images
Dermoid cyst	Hyperintense	Hypointense	No	Fat and calcification, fat-fluid levels
Arachnoid cyst	Hypointense	Hyperintense	No	Isointense to CSF, hypointense on diffusion-weighted images

- ***Brain Tumors evaluation***

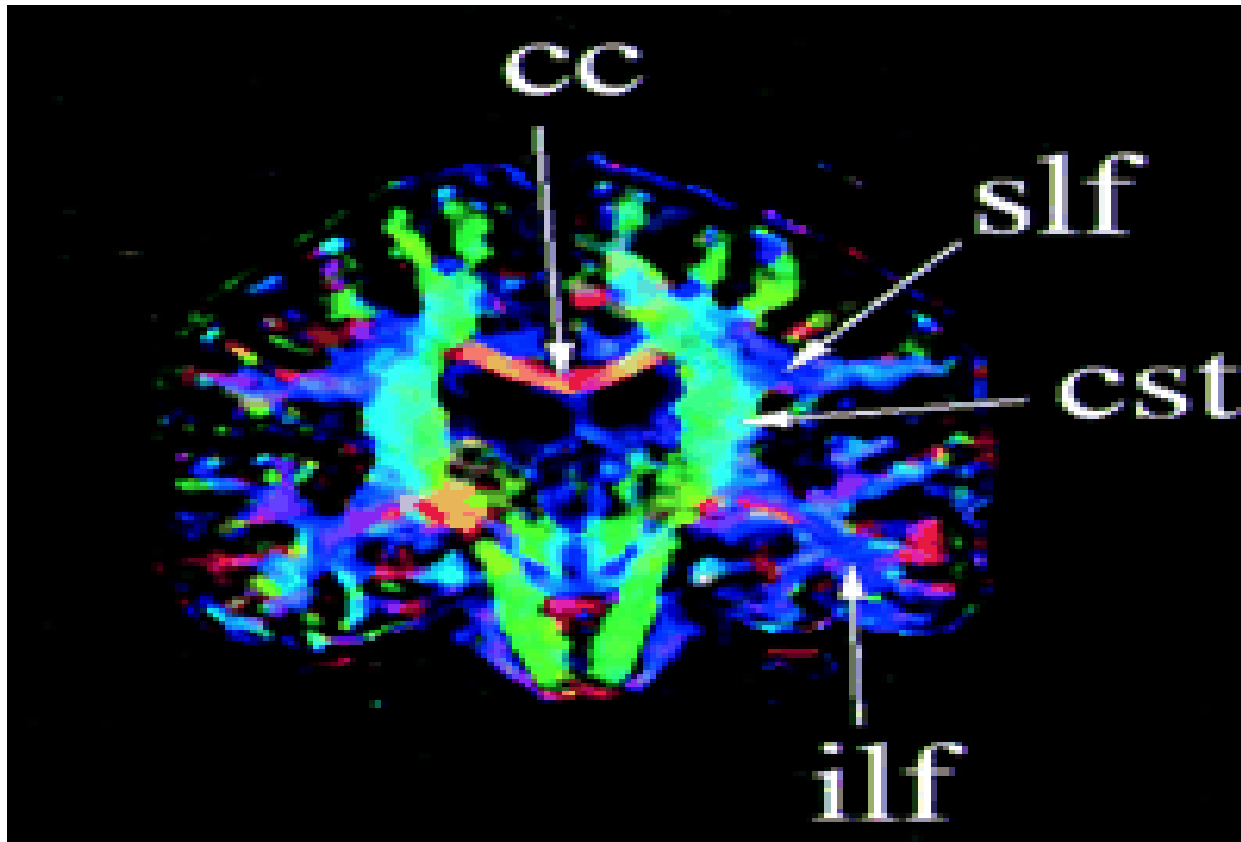
- Highly cellular tumors such as lymphoma, medulloblastoma and meningioma have a lower ADC than the brain parenchyma.
- Not always specific to allow tumor characterization.
- **Viable tumor shows normal-high signal intensity on DWI, decreased ADC**
- **In areas of tumor necrosis, low signal intensity on DWI, increased ADC.**

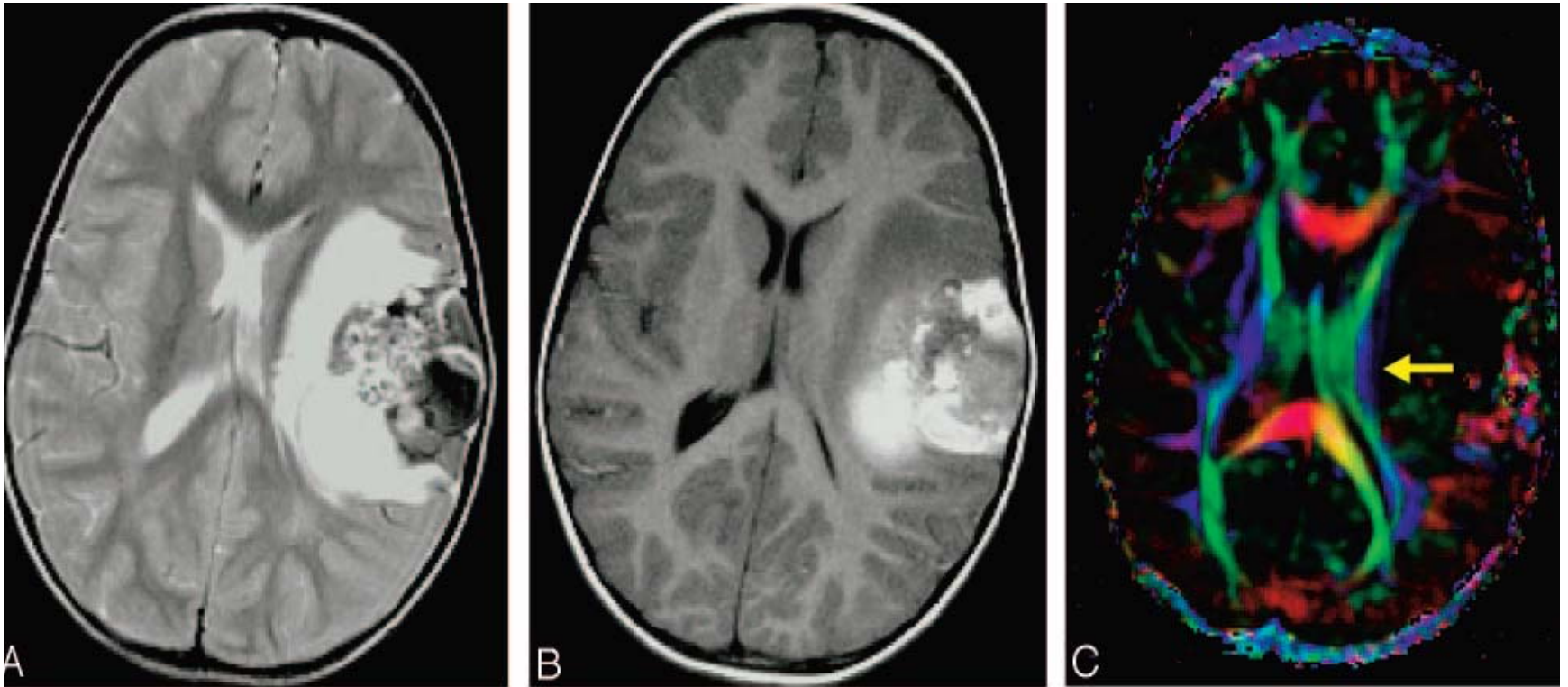


DIFFUSION TRACT IMAGING

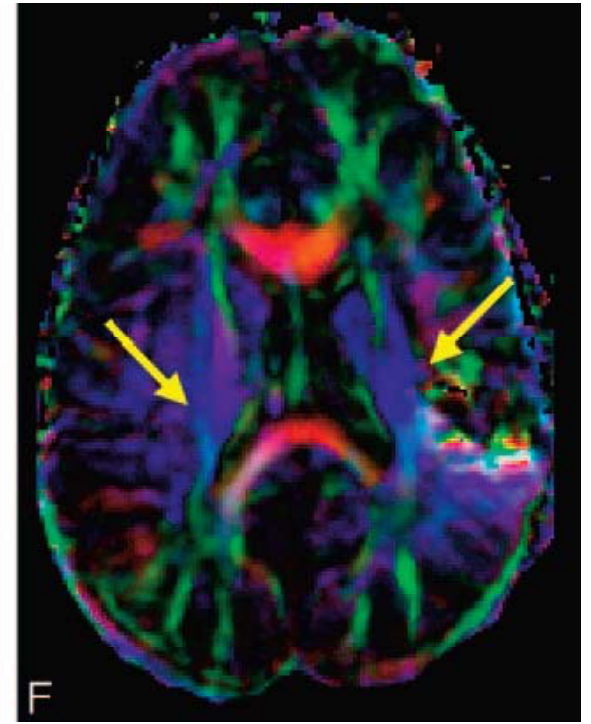
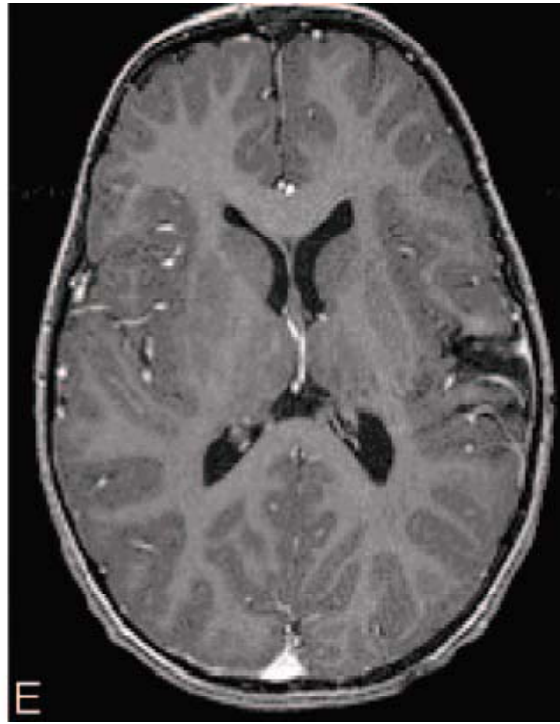
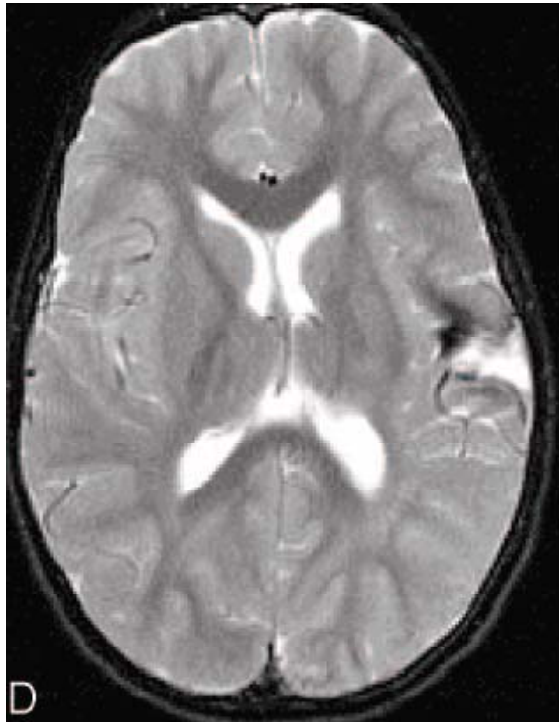
- Special diffusion technique capable of demonstrating white matter tracts and their relationship to lesions.
- **BASIS: Detection of preferential motion of water along white matter fiber tracts.**
- FRACTIONAL ANISOTROPY(FA)-ALIGNMENT OF INTEGRITY
- MEAN DIFFUSIVITY-DENSITY
- Tensor is a map of directional vectors in 3d space

Diffusion tensor MR images in 30-year-old healthy man. cc = corpus callosum, slf = superior longitudinal fasciculus, ilf = inferior longitudinal fasciculus, cst = corticospinal tract





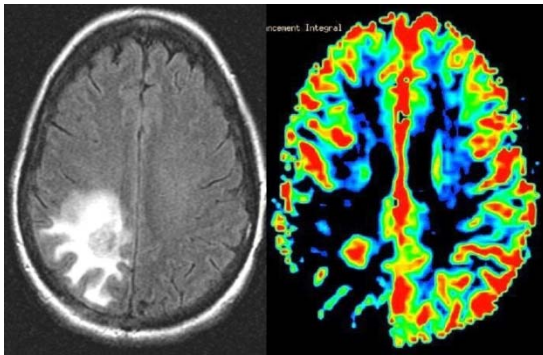
Before surgery,
the color images show postero medial deviation and deformation
(compression) of the posterior limb of the internal capsule (*arrow, C*)



After surgery, the tract appears more symmetric with the contralateral tract (*arrows, F*) in position, cross-sectional shape, and orientation.

USES

- Intraoperative Neuronavigation Using Diffusion Tensor MR Tractography e.g. Tract, optic radiation. Resection of a deep tumor adjacent to the Corticospinal tract.
- This enables researchers to make brain maps of fiber directions to examine the connectivity of different regions in the brain (tractography).
- To examine areas of neural degeneration & demyelination in diseases like Multiple Sclerosis (white matter diseases).



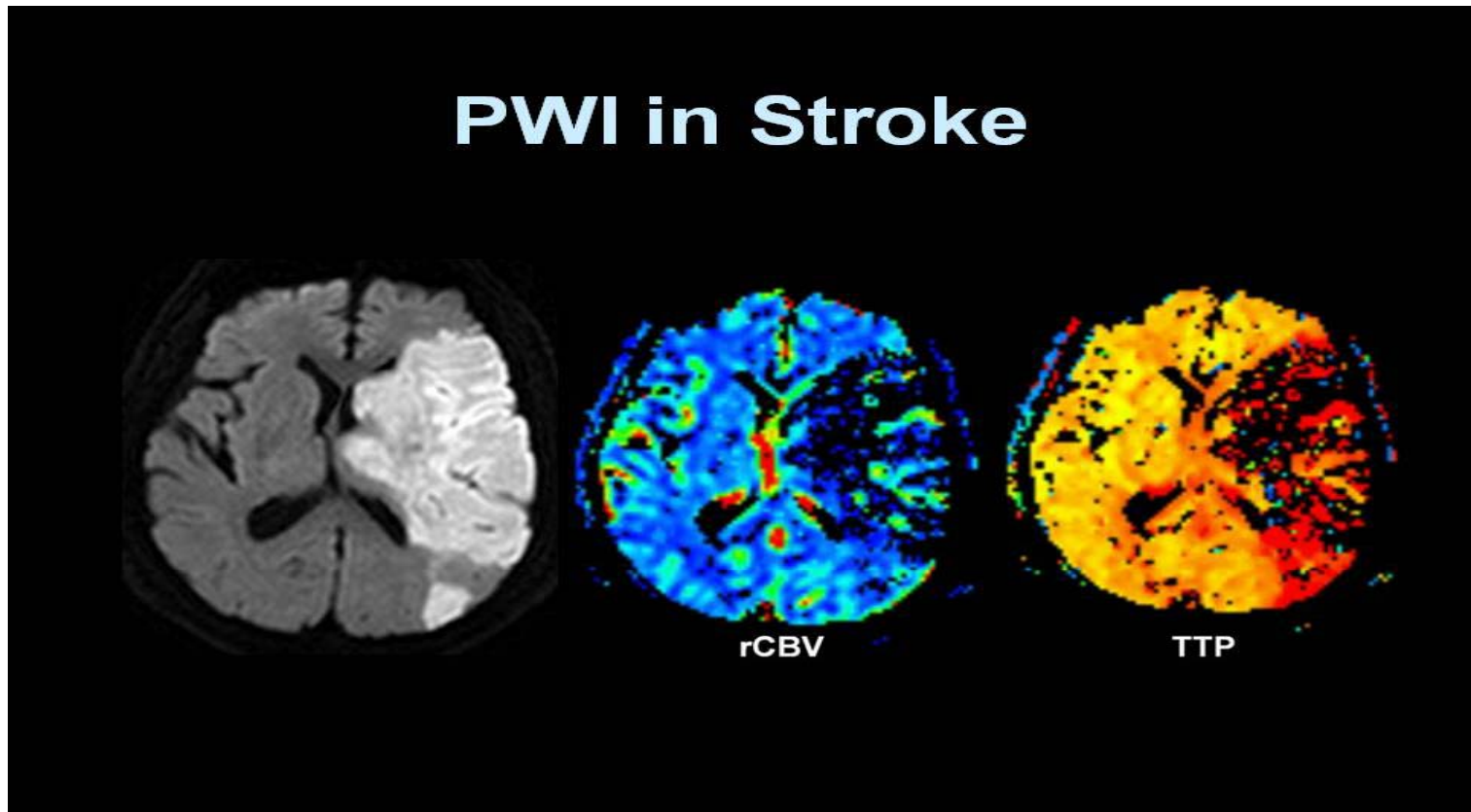
PERFUSION MRI

- Perfusion MRI techniques are sensitive to microscopic levels of blood flow.
- **CONTRAST PASSAGE CAUSES SIGNAL LOSS**
- Method
 - Acquisition of EPI image during rapid bolus of contrast.
 - Gadolinium causes loss of MR signal, most marked on T2* (gradient echo) - weighted & T2 (spin echo) weighted sequences - caused by the magnetic field distorting effects of paramagnetic substances.

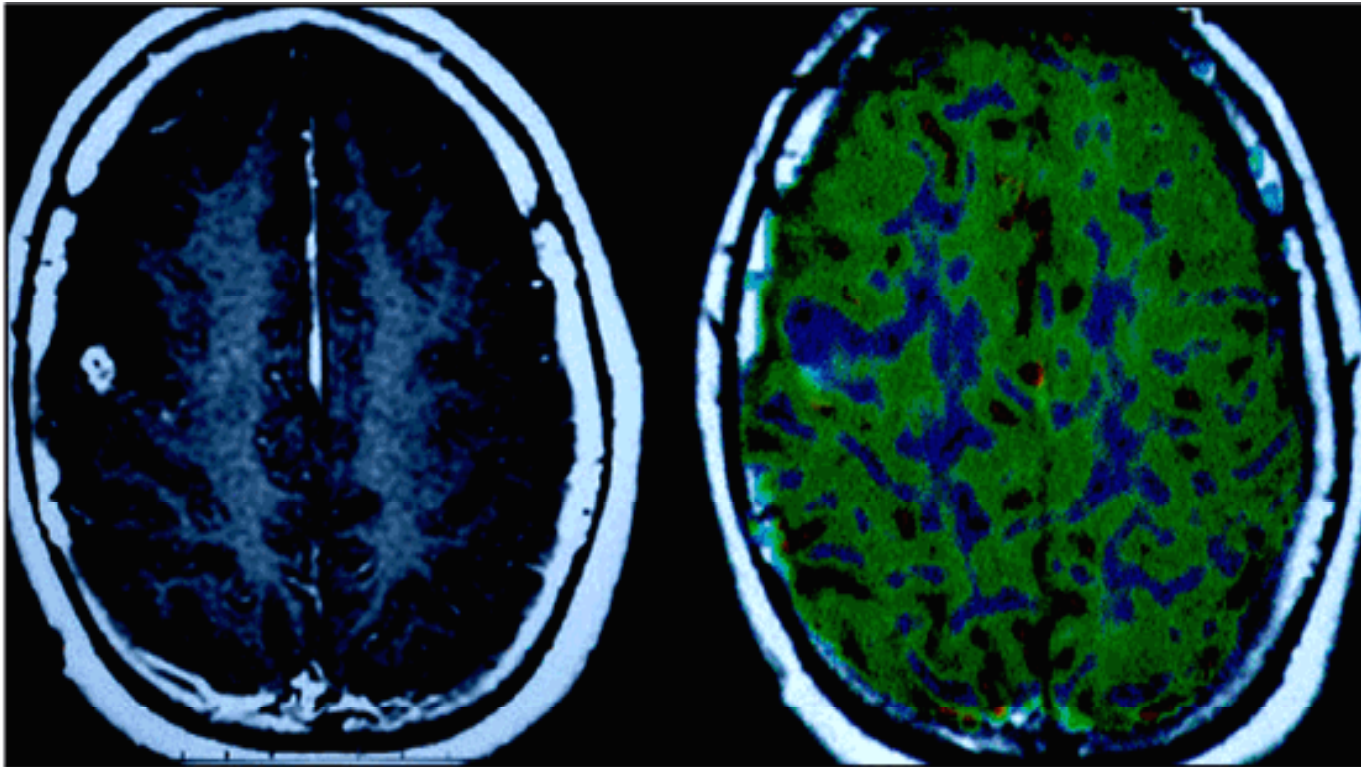
- Passage of contrast causes drop in signal intensity – calculate rate of change of $T2^*$
 - *LINEARLY PROPORTIONAL TO CONTRAST CONCENTRATION.*
- Contrast concentration time course in each voxel is analyzed.
- Data is analyzed to calculate
 - Relative cerebral blood volume (rCBV).
 - Mean transit time (contrast arrival time to time to peak contrast concentration) – MTT.
 - Relative cerebral blood flow (rCBF).

USES

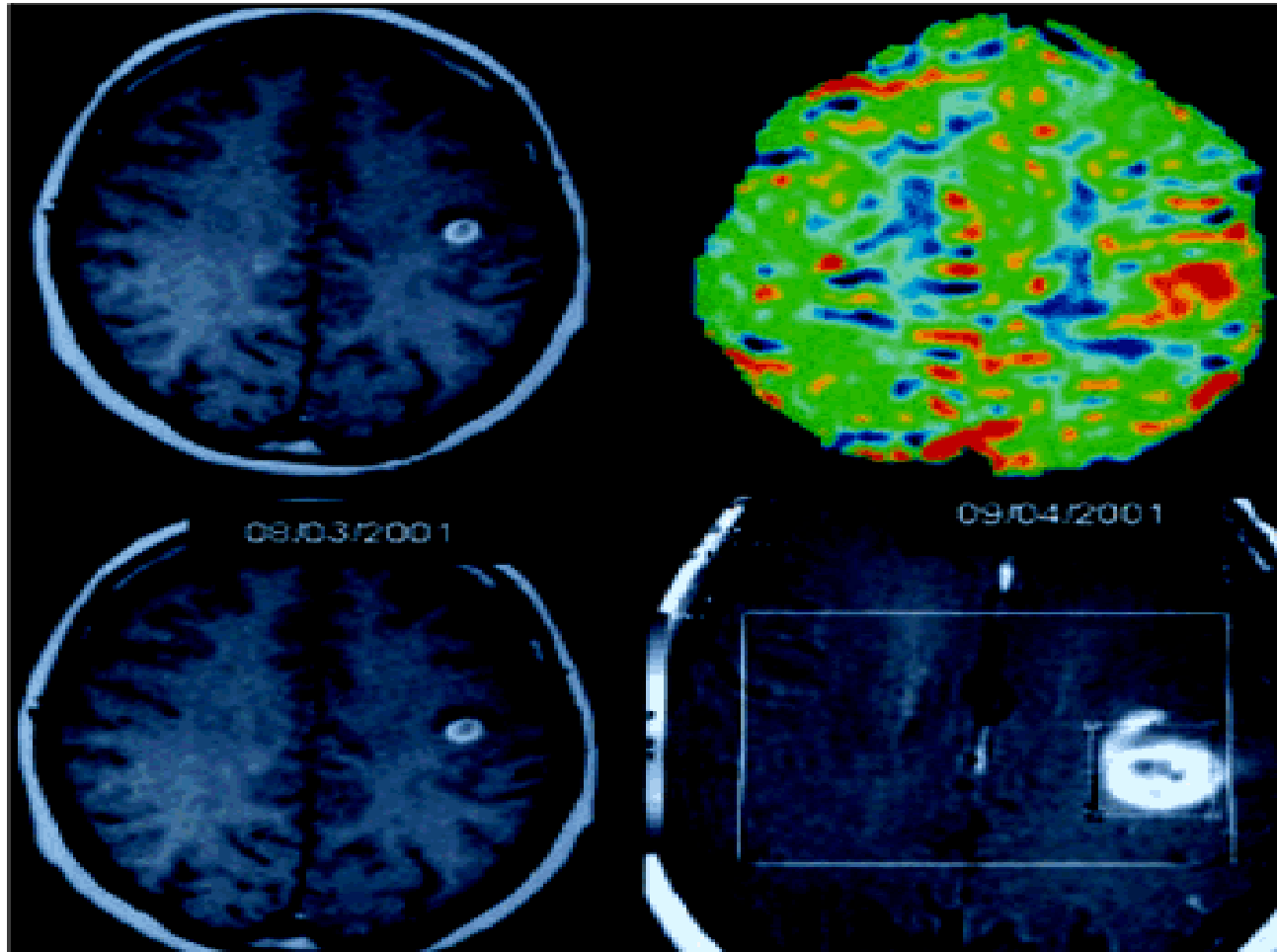
1. Infarction: Delay in mean transit time, reduction in cerebral blood volume, reduced cerebral blood flow.



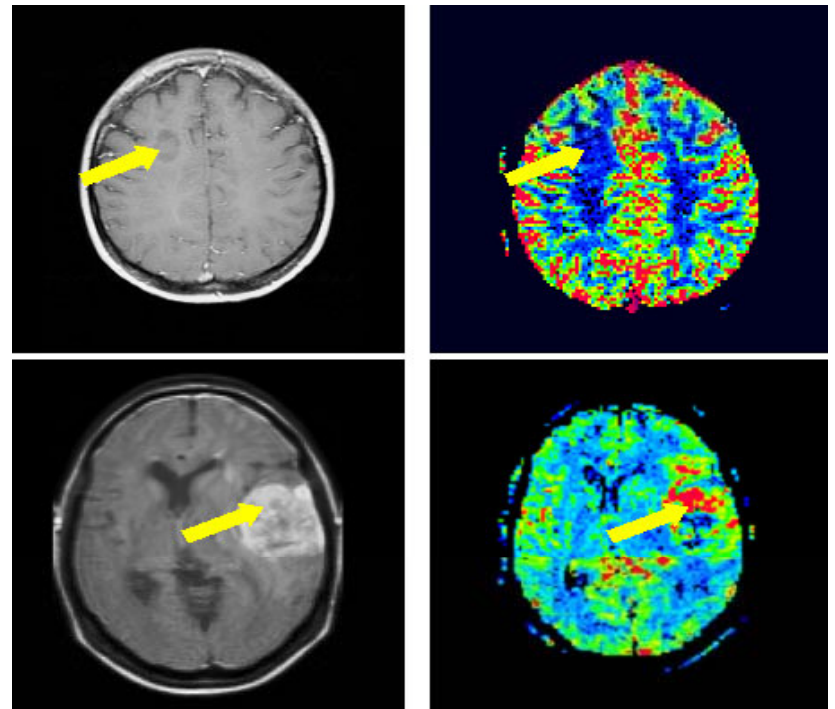
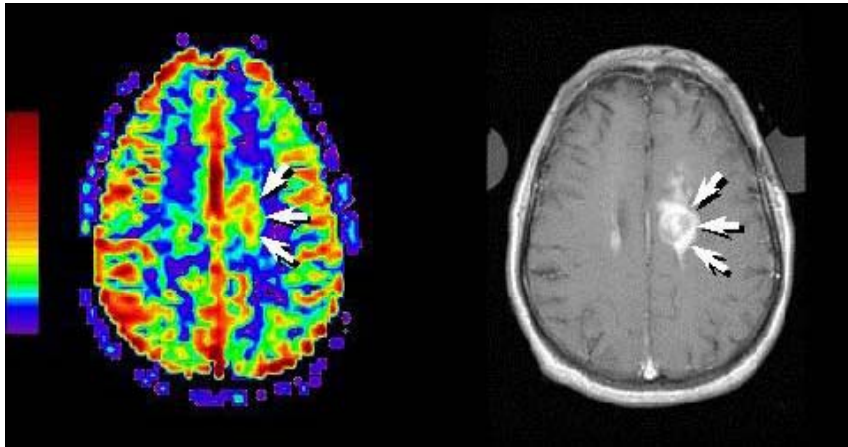
- Differentiating between neoplastic vs. non neoplastic lesion/ extraaxial vs intraaxial



- Assessment of brain tumors-vascularity/grade/site of bx



**Primary brain lymphoma :
lesion shows areas of greatly
increased rCBV (arrows, left
image)**



**In the upper two images,
tumor has a low perfusion,
which indicates a slow-growing
tumor. The lower images show
very high perfusion within the
tumor, which is typical of an
aggressive tumor.**

- Perfusion MRI may be a valuable tool for characterizing and monitoring ischemia in *Moya Moya* disease.
- Perfusion MRI provides additional functional information not available from conventional MRI.
- Has potential role comparable to SPECT in the evaluation of *Moya Moya* disease.

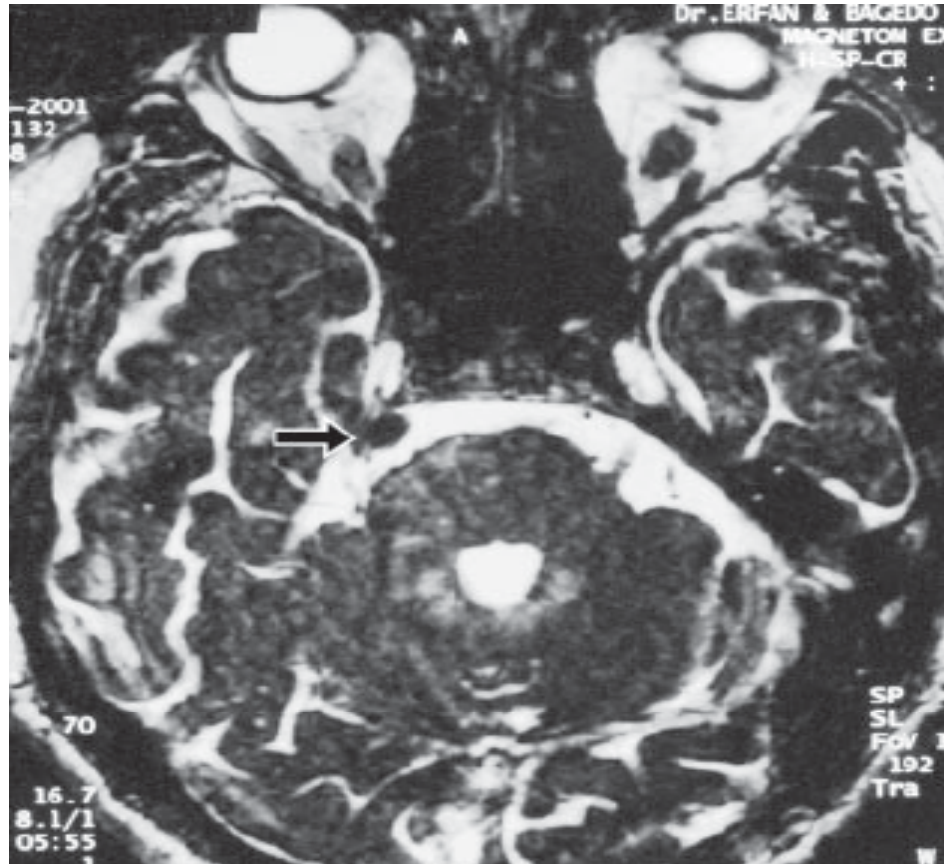
CONSTRUCTIVE INTERFERENCE IN STEADY STATE (CISS)

- Heavily weighted T2 sequence with a strong and constant signal for cerebrospinal fluid.
- This is a 3-D gradient technique, where signal from brain parenchyma is suppressed.
- It gives excellent demonstration of cranial nerves, including the intracanalicular components of eighth nerve. Fluid appears bright.

USES

1. Detailed images of the cerebellopontine angle, internal auditory canals, cranial nerves.
2. PERIOP. Evaluation in endoscopic approach to the intraventricular cysts, suprasellar cysts & the cyst associated with hydrocephalus, located in the midline.
3. 3D CISS MR imaging with MPR (multiplanar reconstruction) is useful in the detection of NVC in patients with trigeminal neuralgia.

Impingement on the rt. 5th N. by the basilar artery in a patient with right trigeminal neuralgia



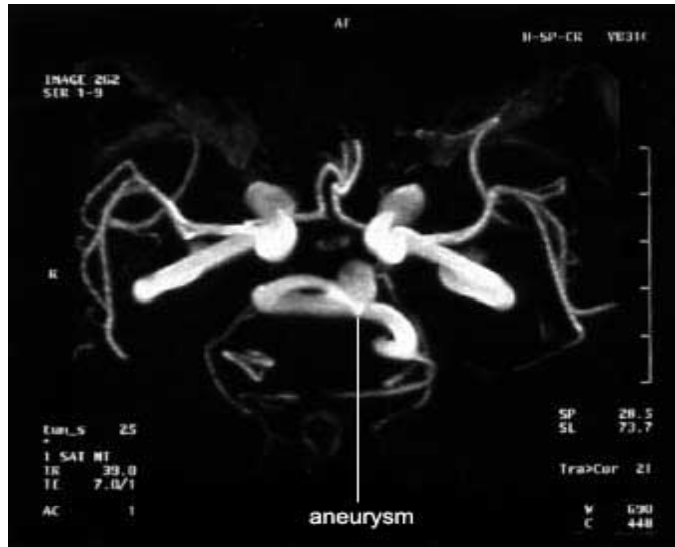
4. In evaluation of brachial plexus injuries, if root avulsion is suspected, CISS is used to perform 3-D MR myelography.

- Uniform signal intensity and high contrast between CSF & neural structures are obtained.
- Enabled detection of meningoceles, avulsed or intact nerve roots, dural sleeve abnormalities & dural scars.
- Evaluation of nerve root integrity - 89% sensitivity, 95% specificity.

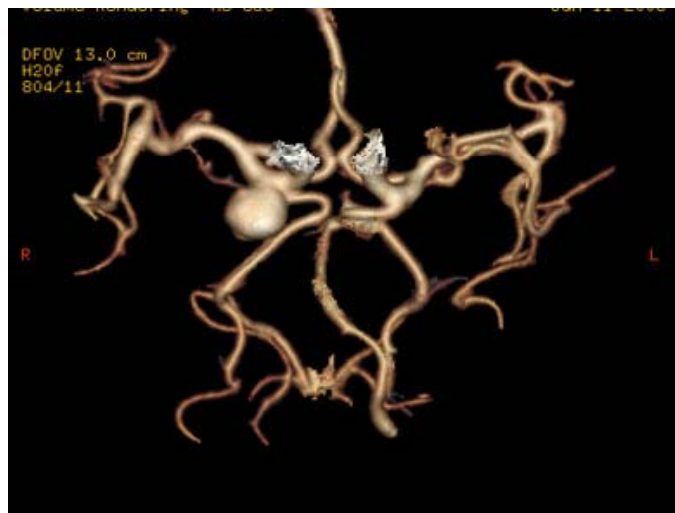
5. Used for evaluation of CSF rhinorrhea (MR cisternography)

- The sensitivity & specificity of the MR method (88.9% & 95.1%) is higher compared with CT cisternography (77.8% & 87.8%).
- Less than 2mm, multiple defects.
- Noninvasive.
- Administration of contrast & agent is no longer necessary.

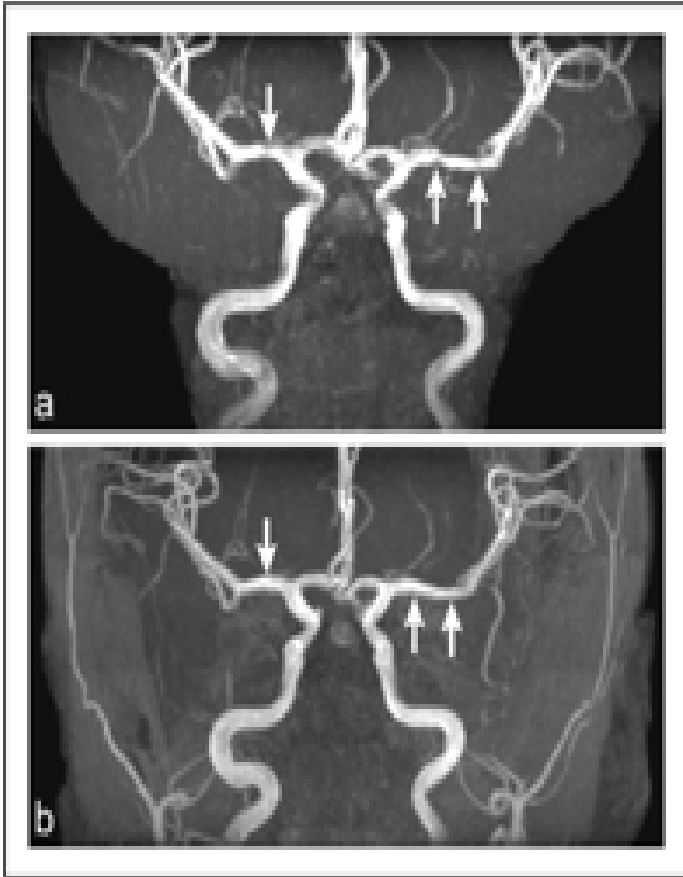MAGNETIC RESONANCE ANGIOGRAPHY



1. Time of Flight MR Angiography
2. Phase Contrast MR Angiography
3. Contrast Enhanced MR Angiography



1. Time-of-flight sequences



- 2D & 3D "flow-related enhancement"
- where most of the signal on an image is due to blood which has recently moved into that plane.
- Vascular flow map rather than anatomic map.

2. Phase contrast MRA :

- Utilizing the change in the phase shifts of the flowing protons. Two data sets with a different amount of flow sensitivity are acquired.
- Longer acquisition time than TOF.
- It can produce anatomic information ,velocity & direction of blood flow.
- **Selective venous & arterial images can be obtained.**

3. Administration of a paramagnetic contrast agent (gadolinium) MRA:CEMRA

- Standard for extracranial vascular MRA. During bolus infusion TOF sequence is used.
- Better evaluates intracranial aneurysms and post coiling follow up of aneurysm.
- Also good in delineating draining veins and nidus of AVM.

USES

1. Excellent for screening of stenosis, occlusion, dissections in carotids of neck.
2. Useful for noninvasive diagnosis of intracranial aneurysm/vascular malformations, especially when contrast angiography is not permitted.
3. ICA & initial branches of ACA, MCA & PCA can be assessed.

DRAWBACKS

- Spatial resolution is poor compared to conventional angiography. Detection of small vessel diseases is problematic.
- MRA is also less sensitive to slow flowing blood and may not reliably differentiate complete from near-complete occlusion
- Motion artifacts by patient or anatomic structure may distort image.
- Signal loss in complex flow.

INTRAOPERATIVE MRI

- Provides real time image guidance .
- Open magnet design/horizontal flat plane design.
- Patient is wheeled in & out for imaging.
- All anesthesia equipment & microscope has to be MR compatible.

USES

- For craniotomy- gliomas , especially deep seated.
- Surgery for intracranial cysts : intraoperative lining of cyst after contrast injection.
- For biopsy of deep seated lesions.
- Transsphenoidal surgery : MR used to optimize angle of entry in sella.
 - Intraop normal gland versus tumor can be identified.
 - Resection guided in large tumors with parasellar extension.

ADVANTAGES

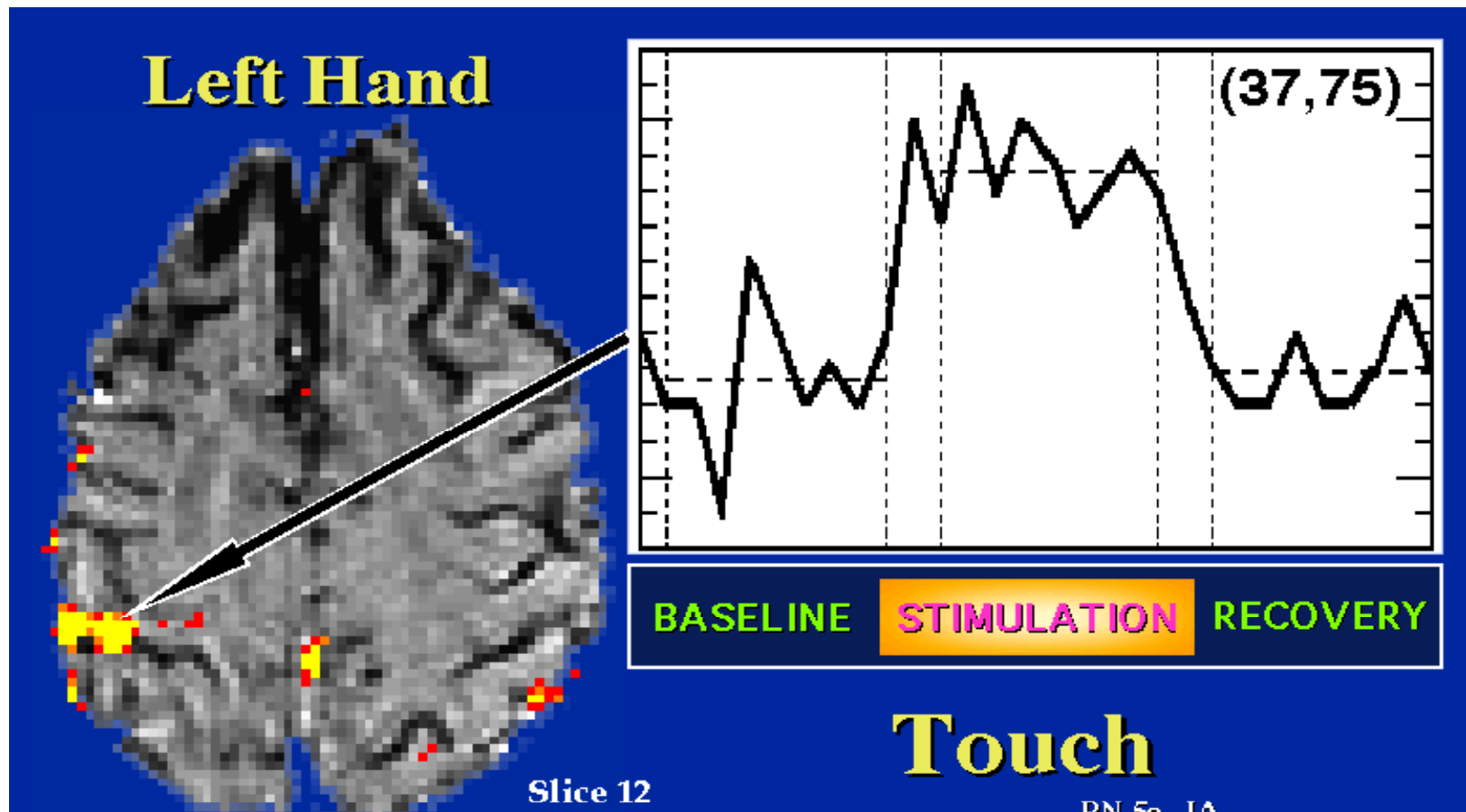
- Accurate real time localization.
- Increased safety of approach through choice of optimal trajectory.
- Definite intraoperative identification of surrounding structures & their relationship to surgical anatomy.
- Immediate evaluation of extent of resection.
- Monitoring of any intraoperative complication e.g. hemorrhage.

FUNCTIONAL MRI

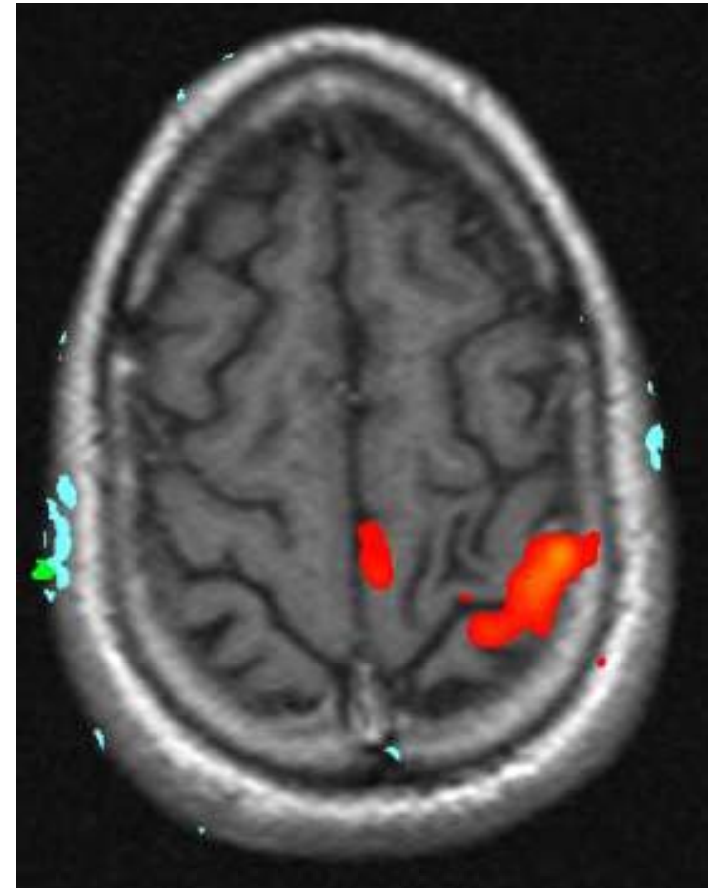
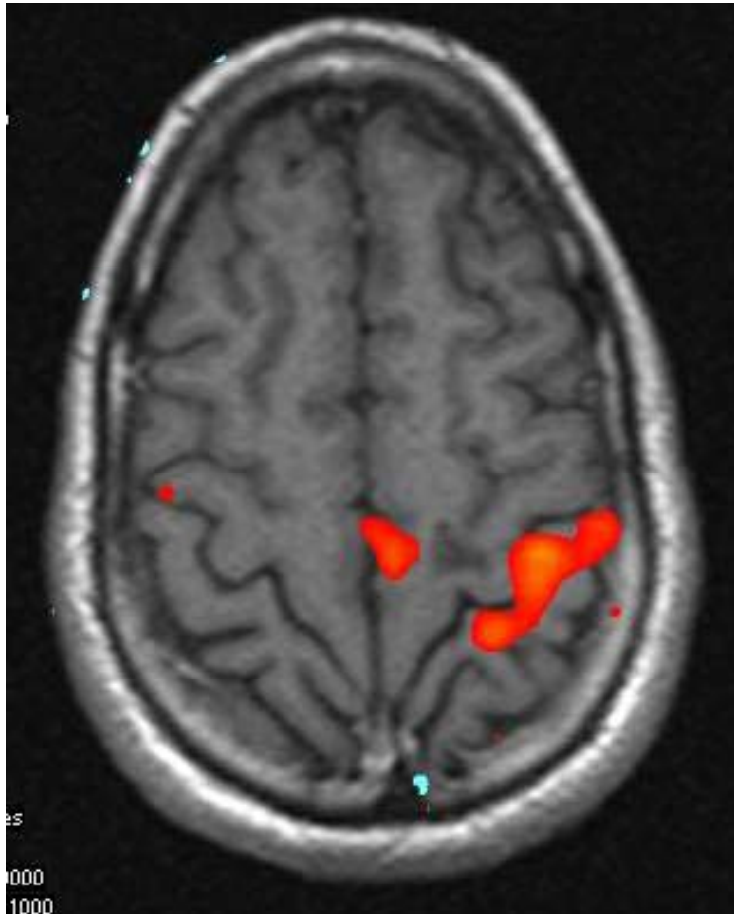
- Functional MRI (fMRI) measures signal changes in the brain that are due to changing neural activity.
- Scanning low resolution but at a rapid rate (typically once every 2-3 seconds).
- Increases in neural activity cause changes in the MR signal via $T2^*$ changes.
- **BOLD (blood-oxygen-level dependent): coupling of neuronal activity and local blood flow.**
- **Deoxygenated Hb is PARAMAGNETIC.**

- Neural activity increases demand for O₂, vascular system over compensates for this, increasing the amount of oxygenated Hb relative to deoxygenated Hb.
- **Because deoxygenated Hb attenuates the MR signal (less paramagnetic), the vascular response leads to a signal increase.**
- Change in intensity is slight (6%) at 1.5T images are repeatedly acquired at same location over course of stimulus using EPI sequence.

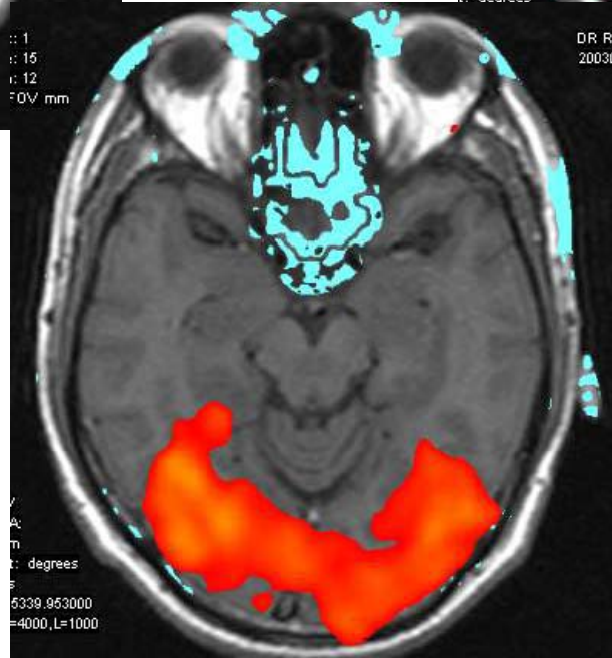
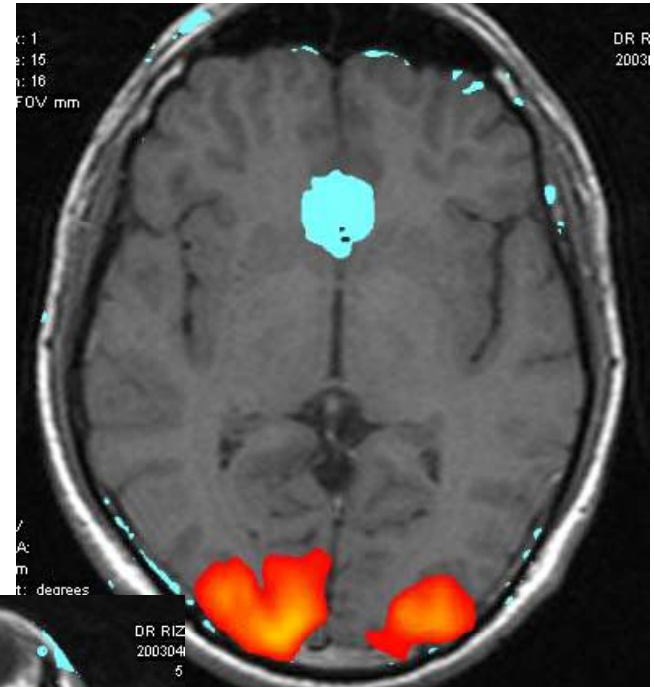
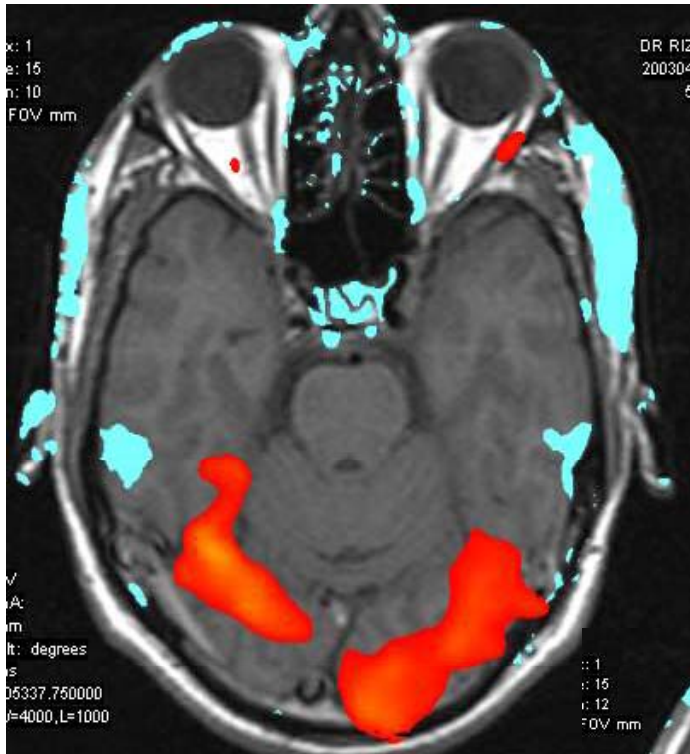
Initial 10 pre-stimulation (baseline) images are followed by 10 activation images (left hand stimulation) and 10 post-stimulation images



GLIOTIC AREA -MOTOR CORTEX



VISUAL ACTIVATION



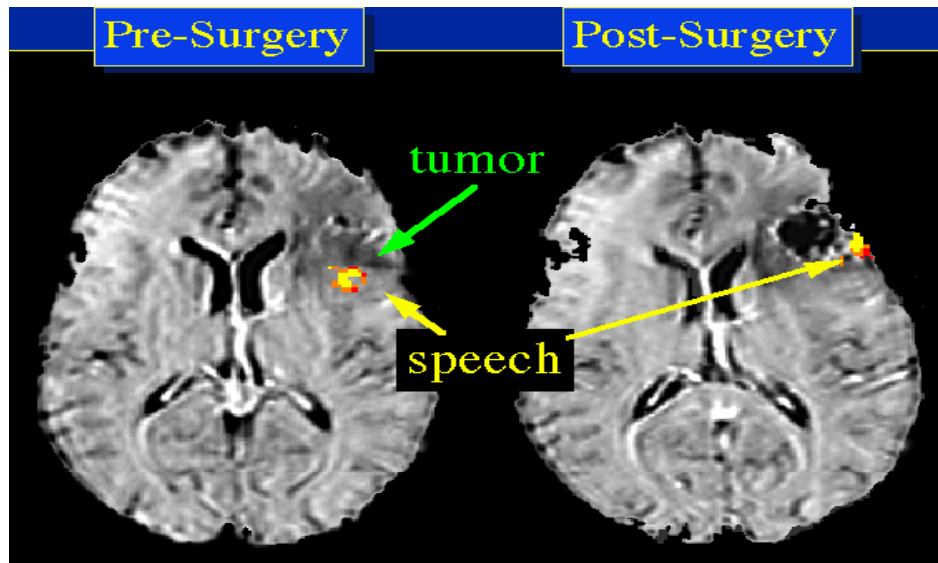
- **LOCALISES:**
 1. Visual cortex
 2. Motor cortex
 3. Somatosensory cortex
 4. Broca's area of speech
 5. Language-related activities.

ADVANTAGES OF fMR

1. Does not require injections of radioactive isotopes, (PET requires it).
2. The total scan time required can be very short, i.e in the order of 1.5 to 2.0 min per run, (PET -multiple acquisitions & therefore, extended imaging times).

1. ROLE IN NEUROSURGICAL PLANNING:

- When the presence of a tumor alters the expected location of a function.
- When the location of the tumor is in an area with an uncertain function such as association cortices or language-related processes.



2. FUTURE ROLE IN PAIN MANAGEMENT

Identification of cortical areas that are modified by the reduction of pain following pain therapy using fMRI to investigate cortical representations of specific pain types.

3. ROLE IN UNDERSTANDING THE PHYSIOLOGICAL BASIS FOR NEUROLOGICAL DISORDERS

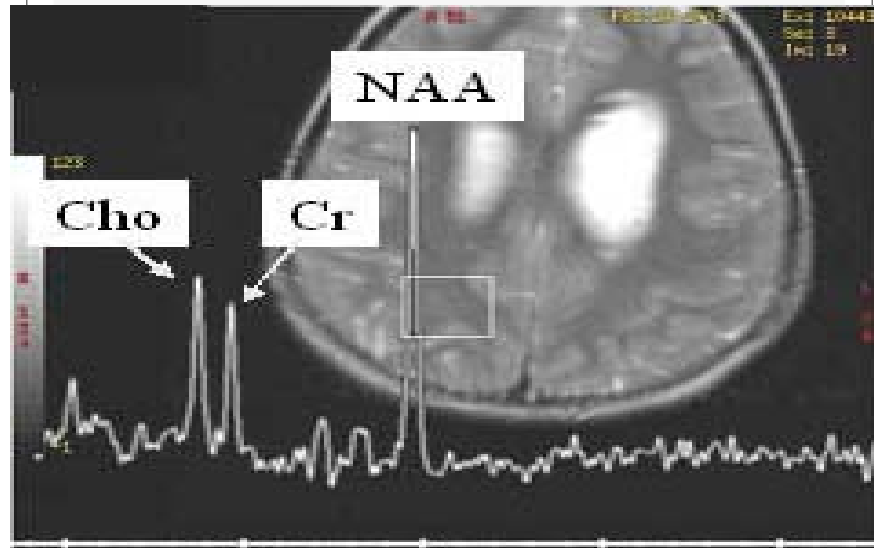
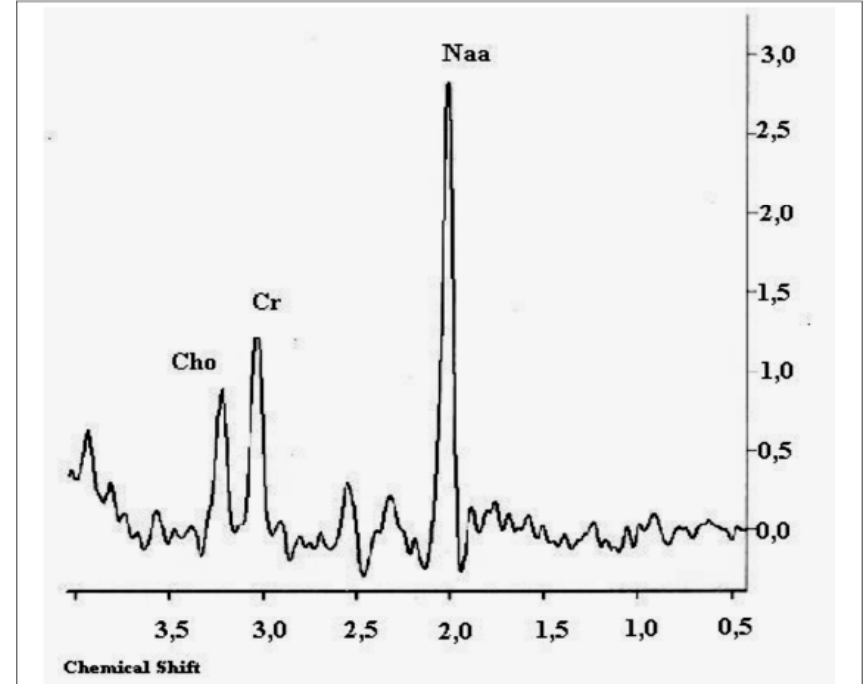
fMRI may contribute to improved precision of seizure localization & understanding of seizure progression & suggests a future direction for investigation.

Magnetic resonance spectroscopy

- Measure the levels of different [metabolites](#) in body tissues-Provides 'metabolic signature' of tissue.
- Method of studying the chemical composition of living tissue *NON INVASIVELY*.
- Chemical elements used: hydrogen, phosphorus, carbon.
- **Proton (^1H) resonance is nowadays the method most frequently used in neuro spectroscopy.**
 - Most abundant atom in the human body nucleus.
 - Emits the most intense radiofrequency signal, when in an external magnetic field.

- Chemical shift is measured in Hz or parts per million (ppm). The preferred unit is ppm.

- **NAA** **2.0 ppm**
- **Cr** **3.0**
- **Cho** **3.2**
- **Lac** **1.3**
- **Lip0** **0.8-1.4**



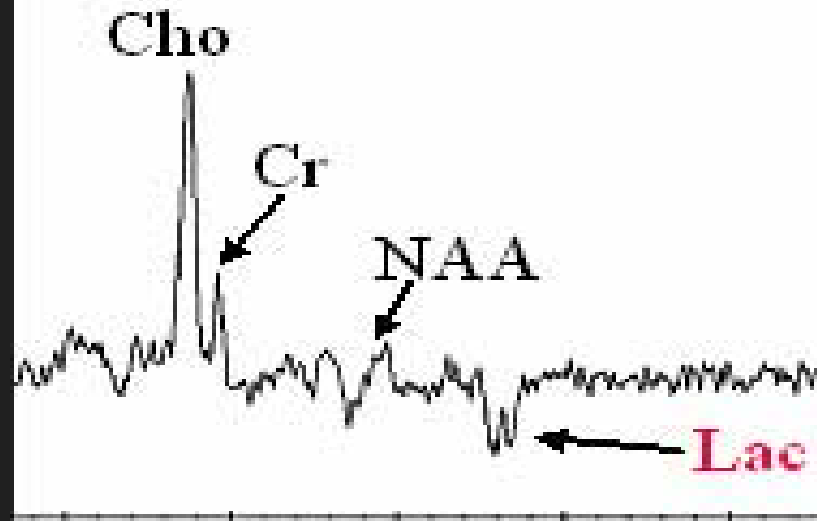
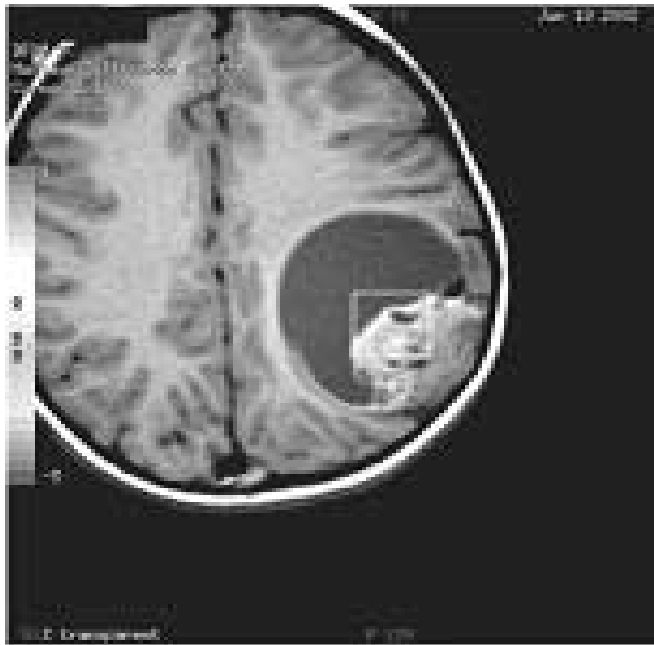- ***N-acetyl aspartate*** : NEURONAL INTEGRITY
- ***Choline*** : CELL TURNOVER
- ***Myoinositol*** –ASTROCYTE MARKER
- ***Amino acids*** are encountered in brain abscesses.
Astrocyte marker
- ***Lipids***-NECROSIS: always pathological-The presence of ***lipids*** is related to necrotic processes.
- ***Creatine***-marker of intact brain metabolism
- ***lactate***: ANAEROBIC GLYCOLYSIS

USES

- **Differential diagnosis of focal brain lesions** (neoplastic & non-neoplastic diseases) : Very sensitive method for detecting brain tumors.
 - **Gliomas : Decreased intensity of the N-acetyl aspartate peak and increased choline occur.**
 - Lactate peaks may be found ,independent of their malignancy grade, indicating hypoxia.
 - Most non- glial tumors have little or no NAA.
 - **Detection of lipids is typical of multiform glioblastoma i.e. tissue necrosis.**
 - ***Multi- voxel spectroscopy is best to detect infiltration of malignant cells beyond the enhancing margins of tumors.***

Tumor recurrence VS Radiation necrosis

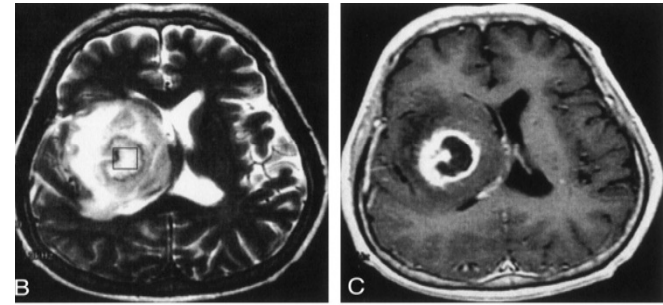
- Elevated choline is a marker for recurrent tumor.
- Radiation change generally exhibits low NAA, creatine & choline .
- If radiation necrosis is present, the spectrum may reveal elevated lipids & lactate.



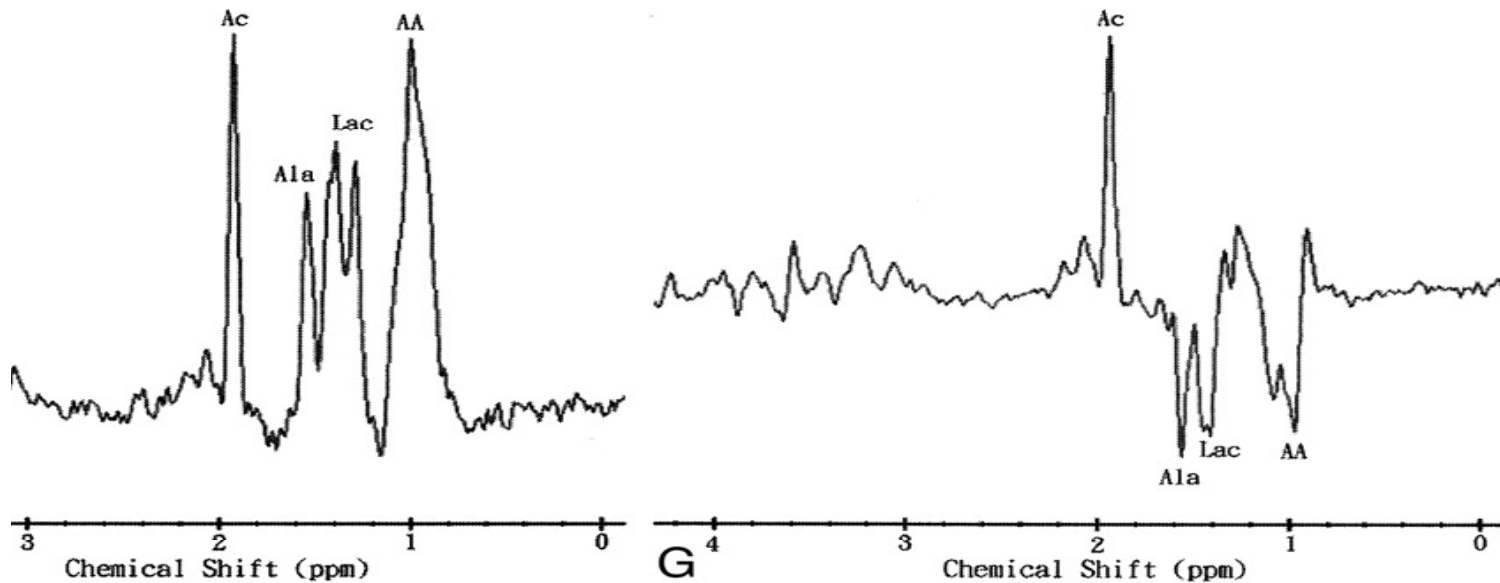
INFLAMMATORY & INFECTIOUS PROCESSES

- Tuberculosis
- ❖ MRS shows a broad lipid peak & occasionally a lactate peak, with a decrease or absence of N-acetyl aspartate & slight increase of choline.

PYOGENIC ABSCESS

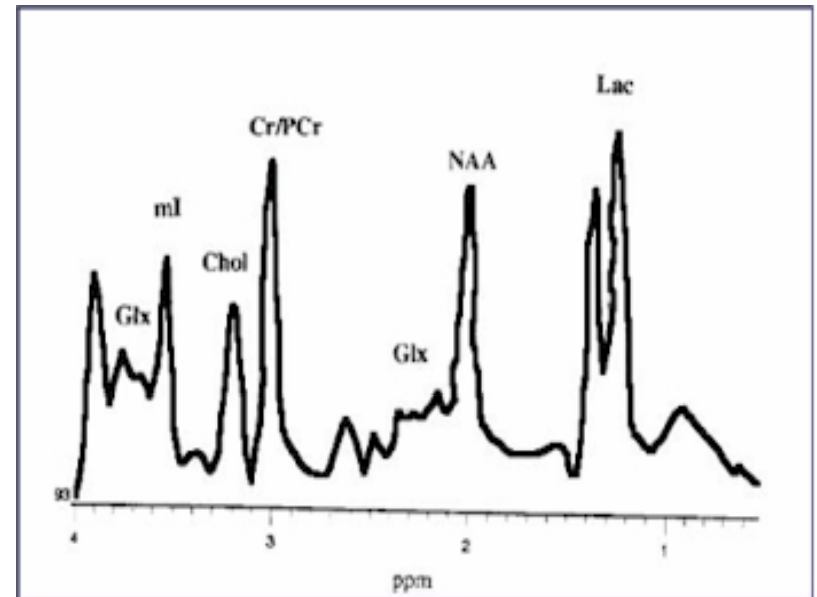


- Amino acid peaks, especially succinate, acetate - due to the great quantity of hydrolytic enzymes produced by bacteria.
- Lactate peak - due to anaerobic metabolism
- N-acetyl aspartate, creatine and choline peaks are not detected.



ISCHEMIC LESIONS

- Early appearance of a lactate peak – anaerobic metabolism
- Decrease of N-acetyl aspartate-neuronal loss
- Slight increase of choline-membrane degradation

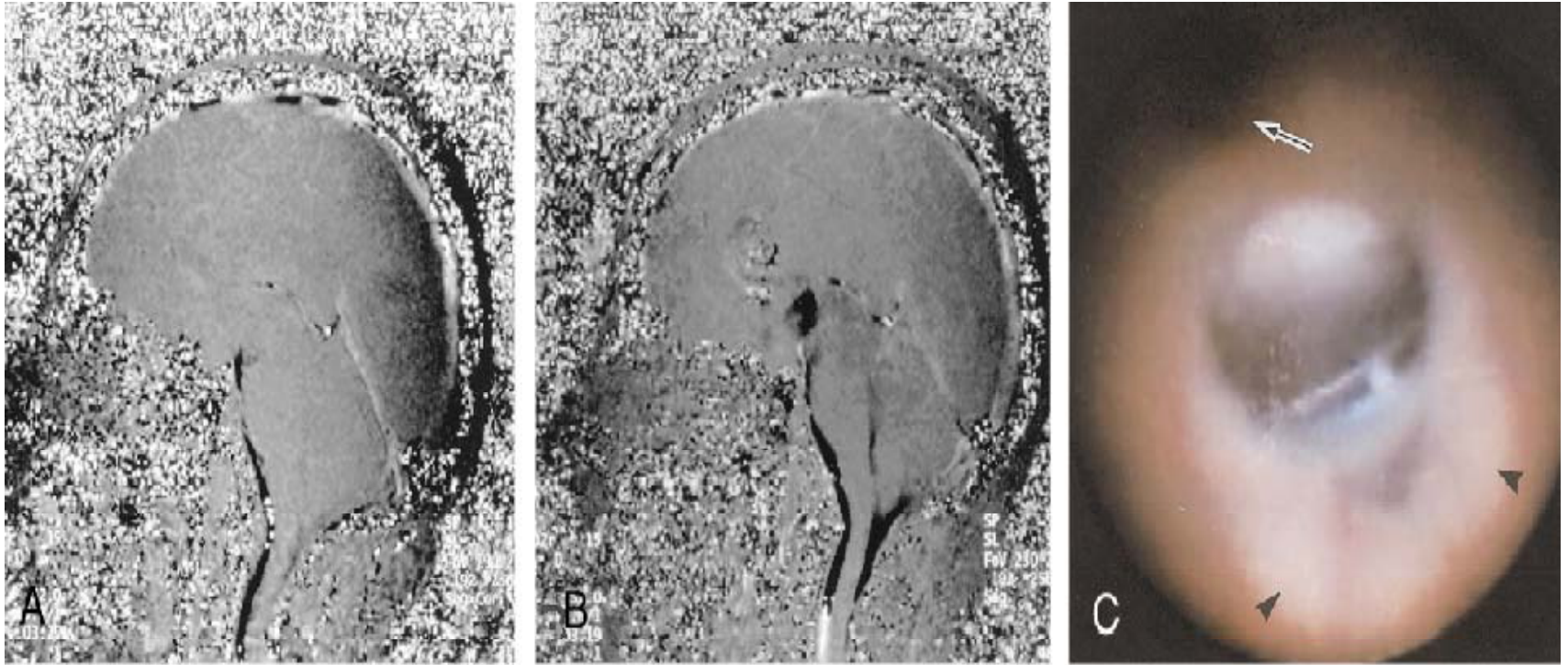


CINE Phase Contrast MRI

- Can demonstrate qualitatively & quantitatively alterations in CSF flow during the cardiac cycle.
- *synchronizes MR data acquisition to a motion cycle to enable imaging of moving tissue.*
- Cine MRI collects image data over many cycles of periodic motion.
- **Used for evaluating cranial & spinal CSF flow.**

USES

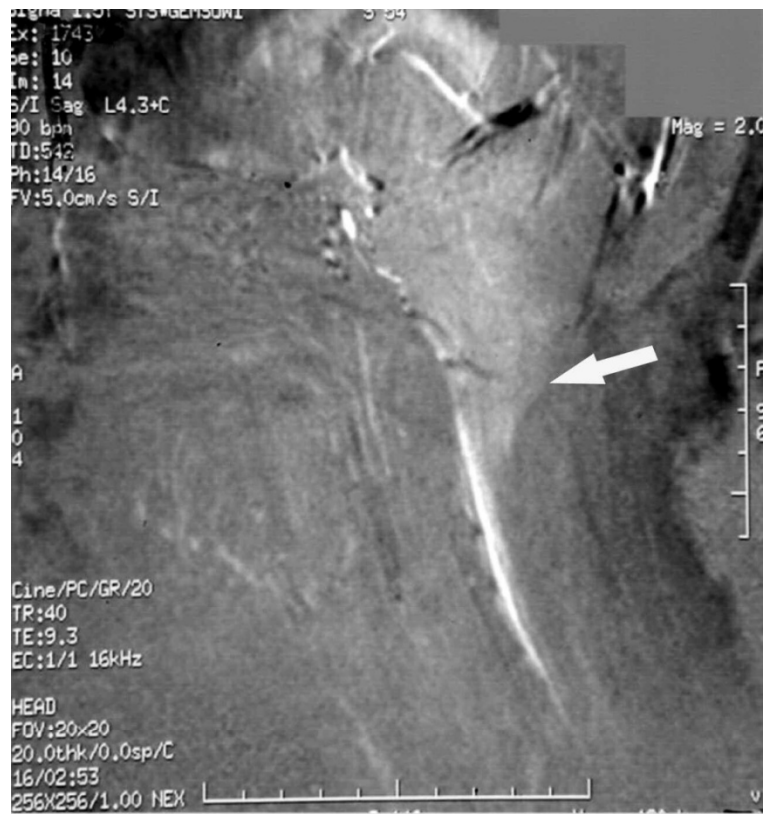1. Physiology of the normal CSF circulation.
2. Pathological CSF flow dynamics in communicating & obstructive hydrocephalus, Chiari malformation, syrinx.
3. Cine MR imaging has been recommended for evaluating the patency of third ventriculostomies.
4. Cerebrospinal Fluid Flow After Endoscopic Aqueductoplasty.



A, Preoperative cine PC MR image reveals obstructive hydrocephalus with no flow in the aqueduct. No flow is apparent in the third ventricle.

B, Cine PC MR image after the third ventriculostomy shows obvious in-phase third ventricular flow, which is categorized as patent. In the anterior horn of the lateral ventricle, an artifact of air is observed.

- Cine MRI: On the left, no posterior flow (arrow) in a patient before decompression of their Chiari I malformation



- Cine MRI, return of CSF flow represented by the white space behind the cerebellar tonsils after decompression (white arrow)

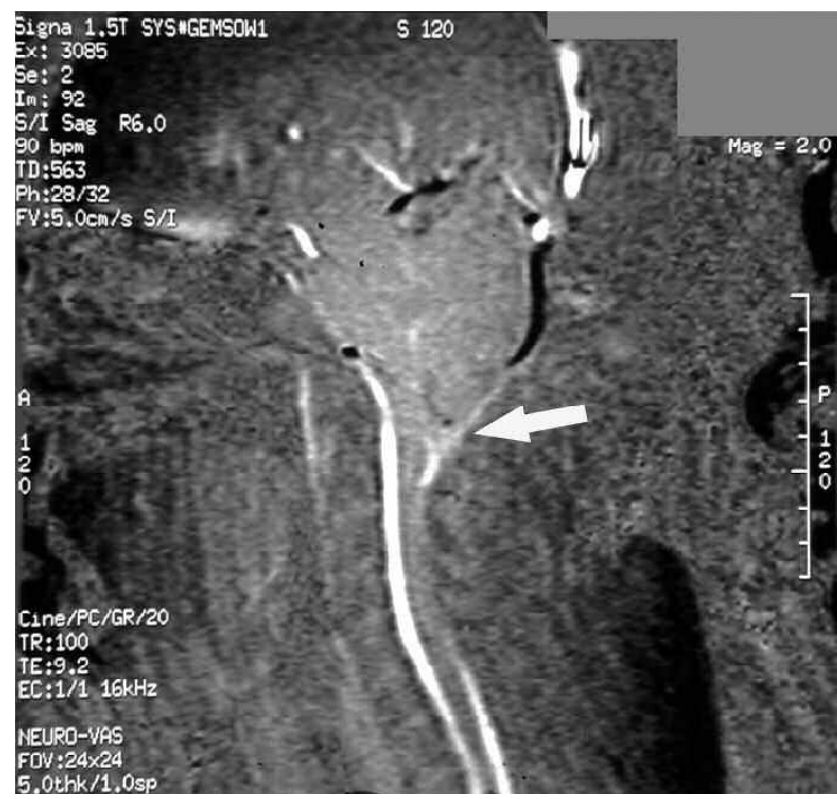

Image Fusion

- Image fusion (exactly overlapping the images in three dimensional space) bring all of the above information together in the operating room.
- This information is used during the course of the operation to help achieve a safer, more effective surgery.
- Intra operative image fusion. gives a "road map" showing unique features of the tumor as well as the location of critical structures that must be avoided to preserve speech, walking and other functions.
- MP-RAGE:3D T1 WT with contrast to make a surgical road map for IMAGE GUIDANCE SURGERY

THANKYOU